

Comparison of paracetamol and fentanyl for pain relief during and after suction termination

Ayça S. Şahin, MD, Aykan Gülleroğlu, MD, Melike K. Toker, MD, Ayşe G. Karabay, MD, Özal Adıyeke, MD, Yavuz Demiraran, MD.

ABSTRACT

الأهداف: لمقارنة مزيج بين الباراسيتامول (20 ملغ / كلغ) والبروبوفول لالفتنانيل (1 ميكروغرام / كلغ) والبروبوفول من حيث قدرته على تسكين الألم والاستشفاء المماثل في إجراءات إنهاء عملية الشفط.

الطريقة: أجريت هذه الدراسة المستقبلية، العشوائية السريرية التي حصلنا عليها الموافقات المستنيرة من 146 امرأة (مجموعة الفنتانيل: 76 [52.1%]، مجموعة الباراسيتامول: 70 [47.9%]) الذي كان من المقرر لعملية كشط مصي في مستشفى اسطنبول قانوني السلطان سليمان للتعليم و التدريب في يناير 2015م. تم توزيع المرضى عشوائياً إلى مجموعة الفنتانيل أو مجموعة الباراسيتامول. وسجلت نتائج مقياس النظر البصري، ودرجات تعديل Aldrete والمعلومات ديناميكي دموي أثناء وبعد العملية الجراحية. وبالإضافة إلى ذلك، تم الاحتفاظ بسجل للأثار الجانبية.

النتائج: عندما تمت مقارنة درجات Aldrete المعدلة في 60 دقيقة، والضغط الانقباضي في 0 دقيقة، تشبع الأكسجين في 10 و 15 و 20 دقيقة، ضغط الدم الانبساطي في 10 و 15 و 20 دقيقة، معدل ضربات القلب وعشرات التماثلية البصرية، لم يكن هناك فرق كبير بين المجموعات ($p < 0.05$). في المجموعة الفنتانيل، كانت ضغط الدم الانقباضي بنسبة 5، 10، 15، 20 دقيقة، وضغط الدم الانبساطي في 5 دقائق وتشبع الأكسجين في 5 دقائق أقل من ذلك بكثير ($p < 0.05$).

الخاتمة: توضح الدراسة أن الخصائص المسكنة للألم، وملامح الاستشفاء والاستفادة من باراسيتامول الوريدي فعالة عند استخدامها في إجراءات إنهاء عملية الشفط. ويتطلب الأمر المزيد من الدراسات.

Objectives: To compare the combination of paracetamol (20 mg/kg) and propofol to fentanyl (1 µg/kg) and propofol in terms of providing adequate analgesia and a comparable recovery profile in suction termination procedures.

Methods: This is a prospective, randomized clinical study in which we obtained informed consents from 146 women (fentanyl group: 76 [52.1%], paracetamol group: 70 [47.9%]) who were scheduled for suction curettage at the Istanbul Kanuni Sultan Suleyman Education and Training Hospital, Istanbul, Turkey in January 2015. Patients were randomly allocated into a fentanyl group or a paracetamol group. Visual analogue scores, modified Aldrete scores, and hemodynamic parameters were recorded during and after the surgical procedure. A record was also maintained of any adverse events.

Results: When the modified Aldrete scores at 60 minutes, systolic pressures at 0 minutes, oxygen saturation at 10, 15, 20 minutes, diastolic blood pressure at 10, 15, 20 minutes, heart rates, and visual analogue scores were compared, there was no significant difference between groups ($p > 0.05$). In the fentanyl group, systolic blood pressures at 5, 10, 15, 20 minutes and diastolic blood pressure at 5 minutes and oxygen saturation at 5 minutes were significantly lower ($p < 0.05$).

Conclusion: Our study demonstrates that the analgesic properties and recovery profiles of intravenous paracetamol is as effective as fentanyl when used in suction termination procedures. Further larger studies are still required.

*Saudi Med J 2016; Vol. 37 (5): 527-532
doi:10.15537/smj.2016.5.15083*

From the Department of Anesthesiology and Reanimation, Istanbul Kanuni Sultan Suleyman Education and Research Hospital, Istanbul, Turkey.

Received 26th January 2016. Accepted 16th March 2016.

Address correspondence and reprint request to: Dr. Ayça S. Şahin, Department of Anesthesiology and Reanimation, Istanbul Kanuni Sultan Suleyman Education and Research Hospital, Istanbul, Turkey. E-mail: aycasultan@gmail.com

Suction curettage is a standard surgical technique and is commonly used for first-trimester pregnancy terminations. One of the important features of this procedure is the shortness of its duration. Patients are typically day cases and are discharged on the same day of the surgery. There can usually be serious pain involved in the procedure;^{1,2} however, patients usually experience pain during gynecologic procedures that involve the uterine cavity.³ Besides ensuring the use of an effective analgesic, another important factor in brief surgical interventions such as suction termination is having a fast recovery time. Paracetamol (acetaminophen; N-acetyl-4 aminophenol) is one of the most widely used analgesics and antipyretics in the world.⁴ Paracetamol is a non-opioid agent, and it is believed that it primarily acts on the central nervous system by way of central cyclooxygenase inhibition, and it probably has an indirect influence on the serotonergic system. It has a good safety profile and easily passes through the blood-brain barrier, which assures it has an effective analgesic.⁵ Opioids are frequently preferred in curettage procedures, and one of the most commonly administered opioids is fentanyl. In general, fentanyl is administered in a dosage of 1 µg/kg during curettage procedures.⁶ Our study was carried out to determine whether the combined administration of fentanyl (1 µg/kg) and propofol or paracetamol (20 mg/kg) and propofol would display similar effects in providing adequate analgesia, and patient and surgeon satisfaction, resulting in a comparable recovery profile.

Methods. We performed a prospective, randomized clinical study in January 2015 at Kanuni Sultan Süleyman Education and Training Hospital, Istanbul, Turkey. The study protocol was approved by the Kanuni Sultan Süleyman Education and Training Hospital Ethics Committee in Istanbul, Turkey. Our study is in accordance with the principles of Helsinki Declaration. Patients who were scheduled for suction termination procedures, fulfilled the inclusion criteria and provide their written informed consent were divided into 2 groups using a computer-generated randomizing system.

The informed consent forms were obtained from 148 women scheduled for suction curettage in the Istanbul Kanuni Sultan Suleyman Education and Training

Hospital between January and February 2015. Patients were randomized into either a fentanyl (1 µg/kg) group or a paracetamol (20 mg/kg) group. Two patients refused anesthesia in the paracetamol group. Thus, 146 patients were enrolled in the study (fentanyl group: 76 [52.1%] and paracetamol group: 70 [47.9%]).

The exclusion criteria were: 1) American Society of Anesthesiologists (ASA) scores⁷ above II, 2) a history of allergic reactions to paracetamol or morphine, 3) a history of paracetamol, opioids or non-steroid anti-inflammatory drug (NSAIDs) use in the 48 hours before requiring chronic analgesic treatment, 4) chronic alcoholism, deficiency of liver and kidney, 5) cardiovascular disease, 6) bleeding diathesis, 7) <18 years of age, 8) body mass index >30 kg/m², and 9) a history of neurological disease, regular sedative medication, and substance abuse. Patients were taken into the operating room, where an intravenous (IV) cannula was inserted. Monitoring consisted of peripheral pulse oximetry, non-invasive blood pressure measurements at 5-minute intervals, and electrocardiography (ECG). After IV propofol (1 mg/kg) was given to each patient, the patients received either an IV fentanyl bolus (1 µg/kg; fentanyl group) or an IV paracetamol bolus (20 mg/kg; paracetamol group) according to the randomization. We recorded the modified Aldrete score, visual analogue scale (VAS), procedure time, and any adverse events such as bradycardia, hypotension, nausea, and vomiting.

The modified Aldrete scoring system (Table 1) was used to measure the patients' recovery time.⁸ Patients were observed for 60 minutes after the curettage procedure. For postoperative pain assessment, the VAS was used (VAS: 0-10; 0: no pain, 10: worst pain imaginable). Intraoperatively, systolic and diastolic blood pressure, heart rate (HR), and peripheral oxygen saturation (SpO₂) values were recorded at 0, 5, 10, 15, and 20 minutes.

Measurements of blood pressure, HR, and SpO₂ were measured at pre-induction of fentanyl and paracetamol, at 5 minutes after induction, and at 5, 10, 15, and 20 minutes following the completion of the procedure. Also, the durations of the surgical procedure and anesthesia were recorded.

For statistical analysis of the data, Number Cruncher Statistical System (NCSS) 2007 (Kaysville, Utah, USA) was used. When evaluating the study data, in addition to the descriptive statistical methods (mean, standard deviation, median, frequency and rate), student's t-tests were used for intergroup comparisons of normally distributed variables and the Mann-Whitney U tests

Disclosure. Authors have no conflict of interests, and the work was not supported or funded by any drug company.

were used for intergroup comparisons of data that was not normally distributed. A *p*-value of <0.05 was accepted as statistically significant.

Results. There were 146 patients involved in this study. When the demographic data, ASA and operation values of the 146 patients were compared (Figure 1), no significant differences were determined between groups (*p*>0.05) (Table 1). Also, no significant differences were found between the 2 groups in terms of VAS and modified Aldrete scores after 60 minutes (*p*>0.05) (Table 2). There was no significant difference

in the HR between groups (*p*>0.05) (Figure 2). In the fentanyl group, systolic blood pressures at 5, 10, 15, and 20 minutes were significantly lower (*p*<0.05) than in the paracetamol group; however, there was no difference between groups at 0 minutes (*p*>0.05) (Figure 3). Diastolic blood pressures at 5 minutes were significantly lower (*p*<0.05) in the fentanyl group; however, there were no differences between groups at 10, 15 and 20 minutes (*p*>0.05) (Figure 4). In the fentanyl group, SpO₂ at 5 minutes was significantly lower (*p*<0.05) than in the paracetamol group, but there

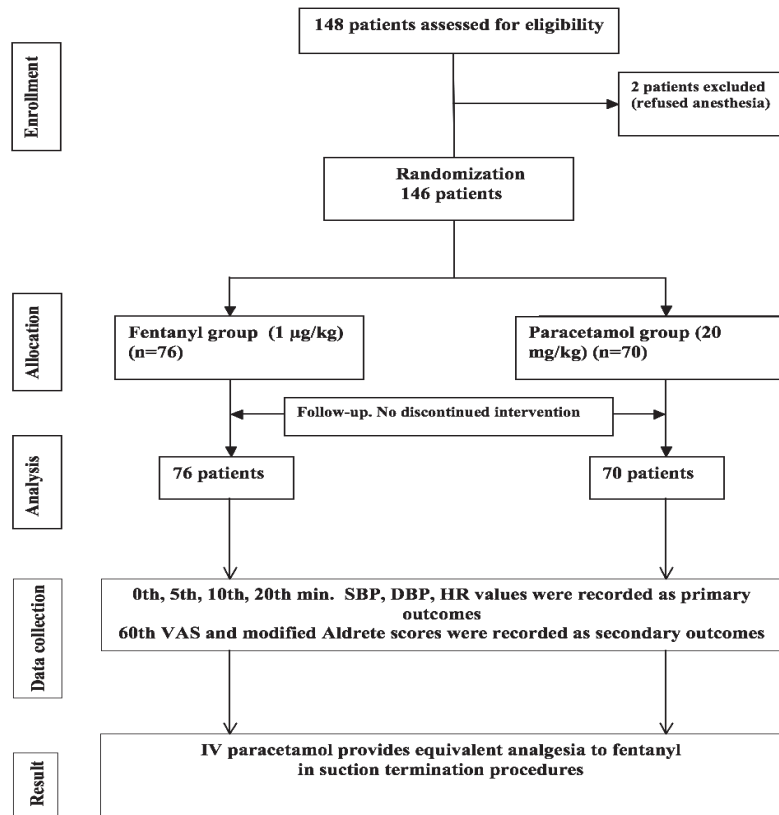


Figure 1 - Flow diagram of 146 women who were scheduled for suction curettage. SBP - systolic blood pressure, DBP - diastolic blood pressure, HR - heart rates, VAS - visual analogue scale

Table 1 - Demographic data of 146 women (fentanyl group: 76 and paracetamol group: 70) who were scheduled for suction curettage.

Demographic data	Total (N=146)	Fentanyl (n=76)	Paracetamol (n=70)	P-value
Age (years)	30.65 ± 6.59	31.54 ± 6.71	29.69 ± 6.36	0.090 ^a
BMI (kg/m ²)	24.90 ± 4.59	25.04 ± 4.98	24.74 ± 4.15	0.693 ^a
ASA I/II (%)	119/27 (100/100)	66/10 (55.5/37)	53/17 (44.5/63)	0.084 ^b
Procedure time (min)	6.18 ± 2.11 (6)	6.17 ± 2.18 (6)	6.20 ± 2.05 (6)	0.793 ^c

The numbers in bracket are presented as median values. ^aStudent t-test, ^bChi-square test, ^cMann Whitney U test, **p*<0.05, BMI - body mass index, ASA I/II - American Society of Anesthesiologists

Table 2 - Visual analogue scale (VAS) and modified Aldrete scores of the patients at 60th minutes ($p>0.05$).

Visual analogue scale	Total (n=146)	Fentanyl (n=76)	Paracetamol (n=70)	P-value
60 th VAS (mid)	3.55±1.77 (3)	3.65±1.92 (4)	3.44±1.61 (3)	0.407 ^c
60 th min modified Aldrete scores	10.00±0.00 (10)	10.00±0.00 (10)	10.00±0.00 (10)	1.000 ^c

^cMann Whitney U Test. The numbers in bracket are presented as median values.

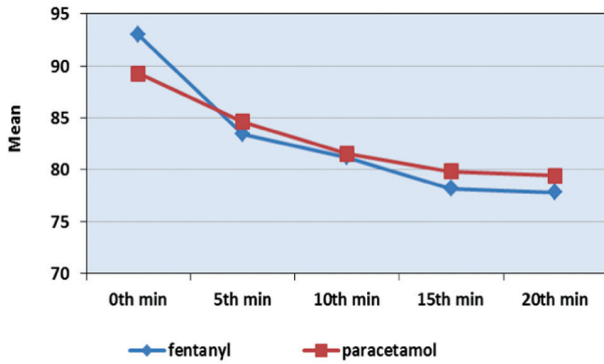


Figure 2 - Heart rates of 146 women who were scheduled for suction curettage. min- minutes

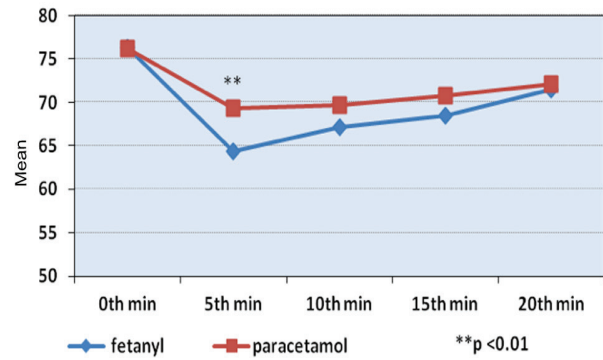


Figure 4 - Diastolic blood pressures of 146 women who were scheduled for suction curettage. min- minutes

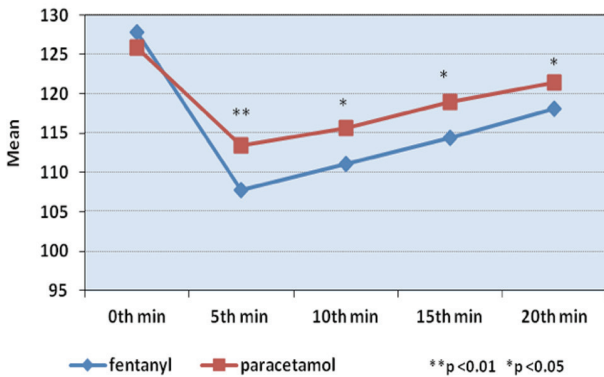


Figure 3 - Systolic blood pressures of 146 women who were scheduled for suction curettage. min- minutes

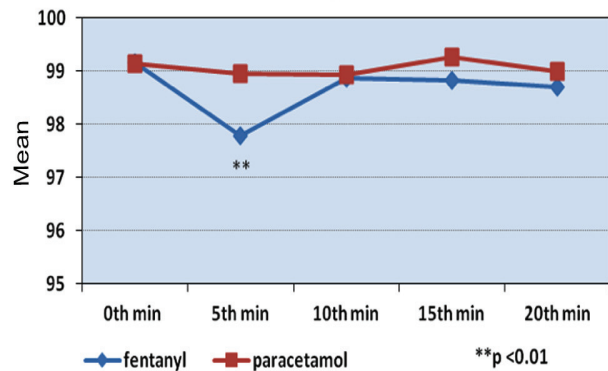


Figure 5 - Oxygen saturation (SpO₂) of 146 women who were scheduled for suction curettage. min- minutes

were no differences between groups at 10, 15, and 20 minutes ($p>0.05$) (Figure 5). No significant differences were found between groups with respect to side effects.

Discussion. Effective pain management is an important component of ambulatory anesthesia. This study demonstrates that 20 mg/kg paracetamol is a safe and effective intravenous nonopioid analgesic for the treatment of postoperative pain management in patients recovering from dilatation and curettage procedure.

In our study, no significant differences were found between the 2 groups in terms of 60th minutes VAS and we did not observe any adverse effects. Gynecological patients have the highest unplanned admission rate in our hospital (85%). Ineffective poorly controlled pain, post-operative nausea and vomiting (PONV), and acute urinary retention are causes resulting in delay in discharge patients after ambulatory gynecologic procedures especially for suction termination procedures.

We have shown that the analgesic properties and usefulness of IV paracetamol are similar to those of IV fentanyl in suction termination procedures. In our study, no significant differences were found between the 2 groups in terms of 60-minute VAS results and we did not observe any adverse effects.

Fentanyl and remifentanyl narcotics are commonly used for perioperative pain relief in brief surgical procedures as these drugs provide good analgesia. Opioid analgesics are effective, but have troublesome and potentially dangerous side-effects, and their potential for abuse may lead to regulatory and logistical difficulties. Fentanyl depress ventilation, induce chest wall rigidity, which might constitute delayed awakening. This effect can delay recovery period. Fentanyl has fewer side-effects, but can still produce dose-dependent respiratory depression, which may contribute to delayed awakening, bradycardia, and hypotension.⁹ These effects can delay discharge in day case procedures.

Paracetamol is used as a non-opioid analgesic. It is an effective and safe drug for managing mild to moderate pain. The IV form of paracetamol passes easily through the blood-brain barrier and shows its central analgesic effects within 15-20 minutes, which start to decline 4 hours after administration. Thus, paracetamol is preferred in most surgical patients for it does not affect mental status, bleeding, respiratory drive, gastric mucosa integrity, or renal function.¹⁰ Ali et al⁹ compared paracetamol and fentanyl for pain relief in dilatation and curettage procedures. They found an insignificant difference between groups and demonstrated that IV paracetamol may be as effective as fentanyl. However, there are not enough studies on this topic, and further large-scale studies are required. Therefore, we undertook this prospective study to examine IV paracetamol as a suitable alternative to fentanyl for perioperative pain, hemodynamic changes and postoperative complications in suction termination of first-trimester pregnancies.

Alhashemi et al¹¹ compared IV paracetamol and oral ibuprofen in patients undergoing lower segment cesarean sections, as the analgesic supplementation agent to morphine. Their results indicated that patients in the IV paracetamol group had better pain control compared to the ibuprofen group. Sinatra et al¹² compared IV paracetamol with a placebo and found that IV paracetamol administered over a 24-hours period in patients with moderate to severe pain after orthopedic surgery provided rapid and effective analgesia and was well-tolerated. Kouček et al¹⁰ compared paracetamol and fentanyl in intensive care unit patients and found

similar pain scores between the two groups and any adverse effects were observed. In our study, no significant differences were found between the 2 groups at the 60-minute VAS, and we did not observe any adverse effects.

Craig et al¹³ compared IV paracetamol and IV morphine for acute limb trauma in an emergency department. The patients received either 1,000 mg IV paracetamol or 10 mg IV morphine. There was no significant difference in the rescue medication, but there were significantly more adverse reactions in the morphine group. There were also no significant differences between the groups in mean pain scores and patient satisfaction. Khan et al¹⁴ examined 84 patients undergoing outpatient knee arthroscopy and compared pain scores and adverse reactions between IV paracetamol (1,000 mg) and IV morphine (0.1 mg/kg) given prior to awakening from general anaesthesia. There was no difference in pain scores between the patients, but there were more adverse reactions, dizziness, nausea, and vomiting in the morphine patients. This study has important implications for discharge times from outpatient surgical hospitals.

In many studies, the 2 groups also showed no differences in terms of noninvasive hemodynamic variables.^{6,9,10} When we compared group HRs, there was no significant difference between the groups. In the fentanyl group, systolic blood pressures at 5, 10, 15 and 20 minutes were significantly lower, and the diastolic blood pressure at 5 minutes was significantly lower. Furthermore, in the fentanyl group, SpO₂ at 5 minutes was significantly lower.

Küçük et al⁶ compared the administration of fentanyl (1 µg/kg) and fentanyl (0.5 µg/kg) in dilatation and curettage procedures. In the fentanyl 0.5 µg group, modified Aldrete scores at postoperative 5 and 10 minutes were significantly higher. In our study, no significant differences were found postoperatively between the 2 groups in terms of modified Aldrete scores at 60 minutes.

Study limitations. Small sample size, lack of placebo arm, single blinded nature, short follow up duration and targeted to a specific population of ambulatory surgeries were reasons we could not draw further conclusions as to the other ambulatory anesthetic procedures such as hysteroscopy, colposcopy, cryotherapy, cone biopsy, and endometrial biopsy.

In conclusion, during moderately painful ambulatory surgical procedures, IV paracetamol may be an asset against opioid analgesics in the control of acute postoperative pain.

References

1. Rattanachaiyanont M, Leerasiri P, Indhavivadhana S. Effectiveness of intrauterine anesthesia for pain relief during fractional curettage. *Obstet Gynecol* 2005; 106: 533-539.
2. Tangsirawatthana T, Sangkomkamhang US, Lumbiganon P, Laopaiboon M. Paracervical local anaesthesia for cervical dilatation and uterine intervention. *Cochrane Database Syst Rev* 2009; (1): CD005056.
3. Trolice MP, Fishburne C, Jr., McGrady S. Anesthetic efficacy of intrauterine lidocaine for endometrial biopsy: a randomized double-masked trial. *Obstet Gynecol* 2000; 95: 345-347.
4. Blough ER, Wu M. Acetaminophen: beyond pain and fever-relieving. *Front Pharmacol* 2011; 2: 72.
5. Arici S, Gurbet A, Turker G, Yavascaoglu B, Sahin S. Preemptive analgesic effects of intravenous paracetamol in total abdominal hysterectomy. *Agri* 2009; 21: 54-61.
6. Kucuk M, Ugur B, Ogurlu M. Comparing the administration of fentanyl 1 microg kg⁻¹(1) and fentanyl 0.5 microg kg⁻¹(1) in dilation and curettage procedures. *Gynecol Endocrinol* 2012; 28: 736-739.
7. Daabiss M. American Society of Anaesthesiologists physical status classification. *Indian J Anaesth* 2011; 55: 111-115.
8. Aldrete JA. The post-anesthesia recovery score revisited. *J Clin Anesth* 1995; 7: 89-91.
9. Ali MA, Shamim F, Chughtai S. Comparison between intravenous paracetamol and fentanyl for intraoperative and postoperative pain relief in dilatation and evacuation: Prospective, randomized interventional trial. *J Anaesthesiol Clin Pharmacol* 2015; 31: 54-58.
10. Kouchek M, Mansouri B, Mokhtari M, Goharani R, Miri MM, Sistanizad M. A comparative study of intravenous paracetamol and fentanyl for pain management in ICU. *Iran J Pharm Res* 2013; 12: 193-198.
11. Alhashemi JA, Alotaibi QA, Mashaat MS, Kaid TM, Mujallid RH, Kaki AM. Intravenous acetaminophen vs oral ibuprofen in combination with morphine PCIA after Cesarean delivery. *Can J Anaesth* 2006; 53: 1200-1206.
12. Sinatra RS, Jahr JS, Reynolds LW, Viscusi ER, Groudine SB, Payen-Champenois C. Efficacy and safety of single and repeated administration of 1 gram intravenous acetaminophen injection (paracetamol) for pain management after major orthopedic surgery. *Anesthesiology* 2005; 102: 822-831.
13. Craig M, Jeavons R, Probert J, Bengler J. Randomised comparison of intravenous paracetamol and intravenous morphine for acute traumatic limb pain in the emergency department. *Emerg Med J* 2012; 29: 37-39.
14. Khan ZU, Iqbal J, Saleh H, Deek AM: Intravenous paracetamol is as effective as morphine in knee arthroscopic day surgery procedures. *Pakistan Journal of Medical Sciences* 2007; 23: 851-853.

Illustrations, Figures, Photographs

All figures or photographs should be submitted in a high resolution (minimum 300 DPI) electronic version saved in jpeg or tiff format. Original hard copies of all figures may be requested when necessary. Photographs will be accepted at the discretion of the Editorial Board. All lettering, arrows, or other artwork must be done by an artist or draftsman. If arrows are used please ensure they appear in a different color to the background color, preferably black with a white border, or white with a black border. If arrows distinguish different items on the figure then different arrow styles should be used ie. long, short, wide, narrow. Written informed consent for publication must accompany any photograph in which the subject can be identified. Written copyright permission, from the publishers, must accompany any illustration that has been previously published.