

## SYSTEMATIC REVIEW

### Optimum level of inferior mesenteric artery ligation for the left-sided colorectal cancer. *Systematic review for high and low ligation continuum*

Guraya compares the effectiveness and impact of high inferior mesenteric artery (IMA) versus low IMA ligation on 5-year survival, lymph node yield rates, and peri-operative morbidity and mortality. Only clinical studies were selected and review articles and meta-analysis were excluded. In cases of duplicate cohorts, only the latest article was included. High ligation was not found to be positively correlated with increased anastomotic leakage or impaired genito-urinary function. However, high ligation demands advanced surgical expertise and longer operating time. There was no significant difference in 5-year survival rates for both techniques. Although there is no consensus, this research signals the routine use of high ligation for left-sided CRC. However, the published fatal complications following high ligation and no significant difference in 5-year survival rates demand more studies to establishing a unified protocol.

see page 731

## ORIGINAL ARTICLE

### The spectrum of congenital heart diseases in down syndrome. *A retrospective study from Northwest Saudi Arabia*

Morsy et al define the frequency and patterns of congenital heart disease (CHD) among children with Down syndrome (DS) in Northwest Saudi Arabia. Children were identified from the unit's data-base and the charts were reviewed retrospectively. Atrioventricular septal defect (AVSD) was the most frequent lesion identified followed by mixed left to right shunt defects, and secundum atrial septal defect (ASD). Ventricular septal defect was detected in 10.7%, and 8.5% had PDA beyond the neonatal period. There was no gender difference in the frequency of CHD ( $p=0.9$ ) and the presence of CHD was not related to the genetic cause of DS ( $p=0.9$ ).

see page 767

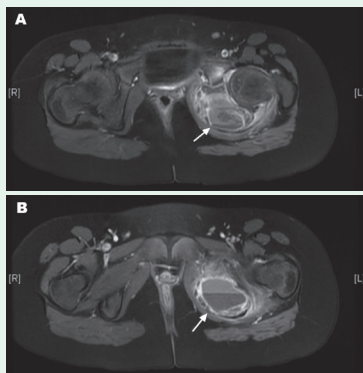
### Epidemiology and clinical consequences of occupational exposure to blood and other body fluids in a university hospital in Saudi Arabia

Samargandy et al describe the epidemiological characteristics, clinical impact, and adequacy of post-exposure management of occupational exposure to blood and body fluids (BBFs). Most percutaneous injuries were caused by hollow-bore needles. Majority of exposures occurred after using the needle/sharp item and before disposal. Two-thirds of exposed individuals were immune to hepatitis B at the time of exposure. With appropriate post-exposure management, none of exposed individuals seroconverted to HIV, hepatitis B or C virus infections. Authors conclude that occupational exposure to BBFs remains a concern among healthcare workers. Educational programs targeting high-risk groups entailing reinforcement of prevention and adherence to post-exposure management guidelines are needed.

see page 783

## CASE REPORT

### Pediatric aneurysmal bone cyst in the ischial region



*Axial MRI of the pelvis showing an expansile lesion arising from the left ischium extending to the inferior pubic ramus with multiple fluid-fluid levels (arrows) of hemorrhagic component (A & B).*

Hetaimish & et al present a rare pediatric case with Aneurysmal bone cyst (ABC) involving the ischial region. A 5-year-old girl presented with left pelvic pain and limping for the past 6 months. Initial imaging showed an expansile lesion in the left ischium, and computed tomography guided biopsy showed giant cells in histopathology study with no evidence of metastasis. The patient underwent intraoperative frozen section followed by extensive intra-lesional bone excision. Bone curettage was pursued along with bone grafting. The case was successfully managed without postoperative complications after the 6-month follow-up period.

see page 799