

Congenital lobar emphysema

A rare cause of hypertension

Tuğçe Tural-Kara, MD, Halil Özdemir, MD, Ergin Çiftçi, MD, Erdal İnce, MD.

ABSTRACT

النفخ الرئوي الفصّي الخُلقي هو مرض نادر يُميّز بالتضخم الرئوي وقد تكون الأعراض السريرية متغيرة اعتماداً على درجة الانسداد القصبي قمنا بعرض حالة نادرة للنفخ الرئوي الفصّي الخُلقي في رضيع يبلغ ٣٨ يوماً الذي قدم مع ضيق تنفسي حاد وارتفاع ضغط الدم وقد لوحظت حبس الهواء في الرئة اليسرى العلوية وتحول منصفى كبير إلى اليمين على الصدر بالأشعة السينية. كشف عن تغيرات نفاخية عبر التصوير المقطعي للصدر واعتباره نفاخ رئوي فصّي خُلقي. استأصل جراحي الأطفال الفص العلوي الأيسر بنجاح ولم تظهر أي علامة على الضيق التنفسي خلال المتابعة التالية للعملية الجراحية وكان ضغط دم المريض سورياً.

Congenital lobar emphysema is a rare disease, which is characterized by pulmoner hyperinflation. Depending on the degree of bronchial obstruction, the clinical presentation may be variable. We report a rare case with congenital lobar emphysema in a 38-days-old male infant who presented with severe respiratory distress and hypertension. Air trapping in the left upper lung and significant mediastinal shift to the right were observed on the chest x-ray. Emphysematous changes were detected on the thorax computed tomography and considered as congenital lobar emphysema. The upper left lobectomy was successfully performed by pediatric surgeons. On postoperative follow up, no sign of respiratory distress occurred and the patient was normotensive. In this report, a case with congenital lobar emphysema, which is a rare cause of respiratory distress and hypertension is discussed.

Saudi Med J 2016; Vol. 37 (7): 796-798

doi: 10.15537/smj.2016.7.13407

From the Department of Pediatric Infectious Diseases, Ankara University Medical School, Ankara, Turkey.

Received 14th December 2015. Accepted 22nd May 2016.

Address correspondence and reprint request to: Dr. Tuğçe Tural-Kara, Department of Pediatric Infectious Diseases, Ankara University Medical School, Ankara, Turkey. E-mail: tugcetural@hotmail.com

Congenital lobar emphysema (CLE) is a rare disease, which affects newborns and infants. It is characterized by air trapping of lung.¹ The incidence is approximately 1 in 70000 to 1 in 90000 live births.² Although in 50% of the cases, etiology is miscellaneous; congenital deficiency of the bronchial cartilage, external compression by vascular abnormalities, congenital Cytomegalovirus (CMV) infection, bronchial stenosis, and bronchial mucosal flaps may be responsible for the etiology.^{3,4} Congenital lobar emphysema may be presented with tachypnea, tachycardia, and retraction. Although patients usually admit to hospital with respiratory symptoms; hypertension is rarely reported in the literature. This case of CLE, which represented atypically with respiratory distress accompanied with hypertension is discussed.

Case Report. A 3600 g male infant with a gestational age of 39 weeks was born by spontaneous vaginal delivery without any postnatal complications. When he was 20-days-old, he admitted to hospital with tachypnea (respiratory rate >60 /minutes) and respiratory distress. He was diagnosed as bronchiolitis, received intravenous teicoplanin, cefotaxime, and clarithromycin treatment. Chest x-ray showed hyperinflation of upper left lobe. He was referred to our clinic due to increased respiratory distress symptoms. Physical examination revealed respiratory rate of 65/min, heart rate of 185 beats/min, blood pressure of 130/70 mm Hg (normal range 95/55 mm Hg - 75/37 mm Hg),⁵ body temperature of 36.1 C°, and pulse oxygen saturation of 85% at room air. In addition, subcostal and intercostal retractions, decreased air flow entry in both lungs, bronchospasm and 1/6 systolic ejection murmur at the left second intercostal space were detected. There

Disclosure. Authors have no conflict of interest, and the work was not supported or funded by any drug company.

weren't any sign of cyanosis, jaundice, or heart failure. Other systemic examination was normal. Laboratory analysis revealed a hemoglobin level of 12.1 g/dl, white blood cell (WBC) count of 10300/mm³, platelet count of 626000/mm³, serum level of C-reactive protein <1 mg/l, and erythrocyte sedimentation rate of 2 mm/h. Liver function tests, blood urea nitrogen, and serum electrolyte levels were normal. Carbondioxide retention was detected on the blood gas analysis. Increased aeration of left upper lobe and significant mediastinal shift to the right were observed on the chest x-ray (Figure 1). Echocardiographic examination was normal. He received inhaled salbutamol, intravenous methylprednisolone, intravenous cefoperazone sulbactam, oral amlodipine, and inhale oxygen treatment with hood. Despite antihypertensive treatment, blood pressure levels revealed high. On the computed thorax tomography, emphysematous change was detected in the upper left lobe, which was considered as CLE

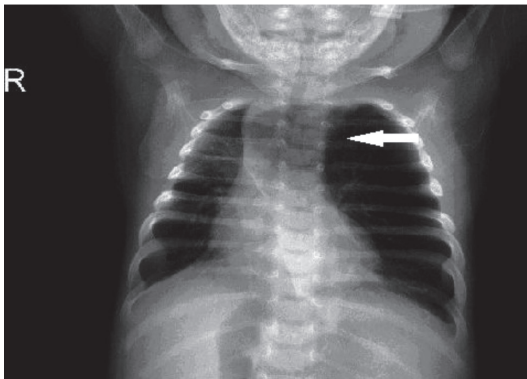


Figure 1 - Preoperative chest x-ray showed increased aeration in the left lobe and mediastinal shift to the right

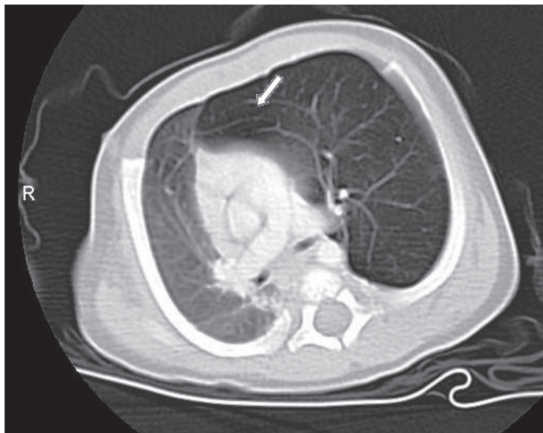


Figure 2 - Emphysematous changes were seen on the thorax CT

(Figure 2). Bronchoscopic examination showed focal hyperinflation in the left upper lobe and lingula, mild pneumothorax at right lung, and bilateral atelectasis at posterior portion of lung. Alpha-1 antitrypsin and Cytomegalovirus (CMV) Ig M levels that are used for identifying the etiology of emphysematous changes were negative. In addition, no etiological agents were detected by polymerase chain reaction analysis of respiratory tract secretions. Hypertension accompanied respiratory distress at the same time. The upper left lobectomy was successfully performed by pediatric surgeons. Pathological examination of the tissue revealed emphysematous changes. On follow-up no sign of respiratory distress occurred. Analgesic treatment for pain relief and amlodipine for hypertension were given. Intravenous cefoperazone sulbactam treatment was ceased at the postoperative sixth day. During the postoperative period, the patient's blood pressure levels remained normal. Control chest x-ray demonstrated air trapping of upper portion of the left lung decreased, and right shift of mediastinum regressed (Figure 3). Despite discontinuation of antihypertensive therapy, patient was normotensive. He was discharged on the postoperative seventeenth day. Informed consent is obtained from parents of the cases described.

Discussion. Congenital lobar emphysema is a rare congenital abnormality characterised by excessive aeration of the lungs. Abnormal interactions between embryonic endodermal and mesodermal components can cause progressive pulmoner hiperinflation.⁶ Massive over distension of the affected lobe and subsequent compression of surrounding structures usually result with respiratory distress.⁷ Although any lobe can be

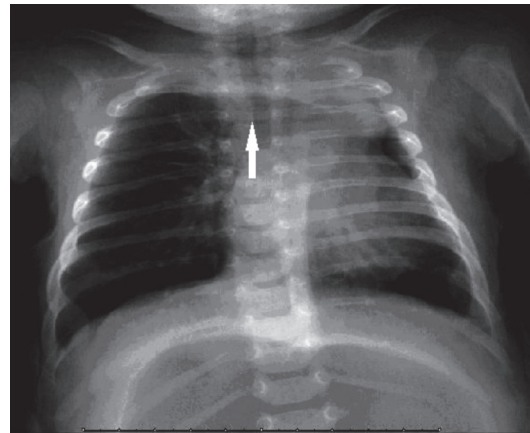


Figure 3 - Postoperative chest x-ray demonstrated healing of right mediastinal shift and midline located trachea.

involved, most commonly affected is left upper lobe.¹ Congenital lobar emphysema is usually identified in full term infants especially up to 6 months. Elderly patients admitted less frequently with wheezing, cough, and recurrent pulmonary infections.⁸ Cardiovascular defects occur in approximately 14% of infants with CLE. Renal agenesis, renal cysts, and limb anomalies may associate this disease.⁹ Depending on the degree of bronchial obstruction, clinical presentation may vary from tachypnea, tachycardia to retraction.¹⁰

Our patient developed respiratory distress in neonatal period. At the admission, he had tachypnea, tachycardia, and retraction. In addition, right shift of mediastinum and exacerbation of respiratory distress occurred. In this case hypertension accompanied with respiratory distress. During this period, kidney function tests were normal. Hypoxia and increased pCO₂ in arterial blood gas analysis were confirmed. He was also dyspneic, which is an extra stressful event for human metabolism. We suggest that all of these factors may lead to sympathetic hyperstimulation, which resulted in tachycardia and hypertension.

Level of respiratory distress and right shift of mediastinum decreased after left upper lobectomy. Respiratory symptoms of patient significantly improved. Furthermore the patient became normotensive. He was discharged from the hospital on the seventeenth postoperative day. Only one case of CLE presented with hypertension in the literature. This case was a 4-month-old boy and had grade I laryngotracheal cleft and severe pulmonary hypertension. Large ventricular septal defect (VSD) was detected with transthoracic echocardiographic examination. In this case, we assume; VSD, which leads to enlarged main pulmonary arteries due to excess blood flow; may be the cause of pulmonary hypertension.¹¹ However, there was no cardiac abnormality in our case.

In conclusion, CLE is a rare disease that may cause a wide spectrum of clinical signs, such as tachypnea, tachycardia, and respiratory distress. In addition, it

may cause hypertension. As a result; clinicians should consider CLE at the differential diagnosis in the presence of simultaneous occurrence of respiratory distress with hypertension.

Acknowledgment. The authors would like to thank Dr. Suat Fitöz from the Department of Pediatric Radiology, Ankara University Medical School, Ankara, Turkey for reviewing the images.

References

1. Abdellah O, Mohamed H, Youssef B, Abdelhak B. A case of congenital lobar emphysema in the middle lobe. *J Clin Neonatol* 2013; 2: 135-137.
2. Abushahin AM, Tuffaha AS, Khalil NK, Ismeal AM. Bilateral congenital lobar emphysema: A rare cause for respiratory distress in infancy. *Ann Thorac Med* 2012; 7: 250-252.
3. Cataneo DC, Rodrigues OR, Hasimoto EN, Schmidt Jr AF, Cataneo AJ. Congenital lobar emphysema: 30-year case series in two university hospitals. *J Bras Pneumol* 2013; 39: 418-426.
4. Carrol ED, Campbell ME, Shaw BN, Pilling DW. Congenital lobar emphysema in congenital cytomegalovirus infection. *Pediatr Radiol* 1996; 26: 900-902.
5. Nuntnarumit P, Yang W, Bada-Ellzey HS. Blood pressure measurements in the newborn. *Clin Perinatol* 1999; 26: 981-996.
6. Pariente G, Aviram M, Landau D, Hershkovitz R. Prenatal diagnosis of congenital lobar emphysema: case report and review of the literature. *J Ultrasound Med* 2009 ;28: 1081-1084.
7. Tempe DK, Virmani S, Javetkar S, Banerjee A, Puri SK, Datt V. Congenital lobar emphysema: pitfalls and management. *Ann Card Anaesth* 2010;13: 53-58.
8. Santra A, Dutta P, Manjhi R, Pothal S. Congenital lobar emphysema presenting at late childhood: A rare case report. *Lung India* 2014; 31: 302-304.
9. Gorostidi F, de Buys Roessingh A, Gonzalez M, Simon C, Monnier Y. Congenital lobar emphysema presenting as an airway foreign body. *Int J Pediatr Otorhinolaryngol* 2015; 79: 2450-2452.
10. Gogia AR, Bajaj JK, Husain F, Mehra V. Anaesthetic management of a case of congenital lobar emphysema. *J Anaesthesiol Clin Pharmacol* 2011; 27: 106-108.
11. Punj J, Pandey R, Singh B, Darlong V. Management of a grade I laryngotracheal cleft in a 4-month-old child with congenital lobar emphysema and severe pulmonary hypertension. *Acta Anaesthesiol Scand* 2007; 51: 958-960.