In this issue

REVIEW ARTICLE

A review of glycemic efficacy of liraglutide once daily in achieving glycated hemoglobin targets compared with exenatide twice daily, or sitagliptin once daily in the treatment of type 2 diabetes

Alshali & Karawagh review the efficacy of liraglutide once daily in achieving clinical guidelines-recommended glycated hemoglobin A1c levels in patients with type 2 diabetes (T2D) compared with exenatide twice daily, or sitagliptin once daily, based on published literature, with an aim to elucidate the preferred choice of incretin-related therapy in treating uncontrolled T2D. Incretin-based therapies such as glucagon-like peptide-1 (GLP-1) receptor agonists (RA) and dipeptidyl peptidase-4 (DPP-4) inhibitors have gained prominence in recent years for the treatment of T2D. Such therapies offer the potential to stimulate endogenous insulin activity in proportion to circulating glucose levels; thereby, lowering the risk of hypoglycemic episodes. The synthetic GLP-1 RA exenatide, the human GLP-1 RA liraglutide, and the DPP-4 inhibitor sitagliptin are the first agents in their respective classes to be approved for the treatment of T2D and their efficacy and safety has been studied extensively in clinical trials.

see page 834

ORIGINAL ARTICLES

The declining rates of hepatitis B carriage among adolescents and young people in the Eastern region of Saudi Arabia

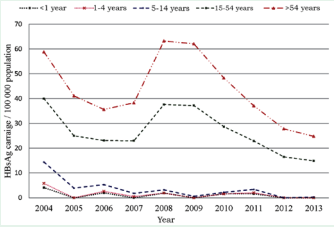

Yearly hepatitis B surface antigen (HBsAg) virus rate/100 000 of hepatitis B among all age groups

Al-Jubran et al conclude that there is a particular decreased trend in the prevalence of hepatitis B virus (HBV) infection in different age groups over a decade of surveillance following more than 20 years of the universal HBV vaccination program. The study shows that the overall prevalence rate decreased from 18.8 to 9.9/100,000 population between 2004 and 2013 (p=0.01). It was also found that the prevalence rate increased with age. Another significant reduction in the prevalence rate occurred among age groups 5-14 years old (p=0.00). An insignificant decrease in the rate by 43% was also seen among older patients of 15-44 years old and 35% in >45 years old. The overall prevalence of hepatitis B is significantly higher in men than in women (p=0.00).

see page 864

Retention practices and factors affecting retainer choice among orthodontists in Saudi Arabia

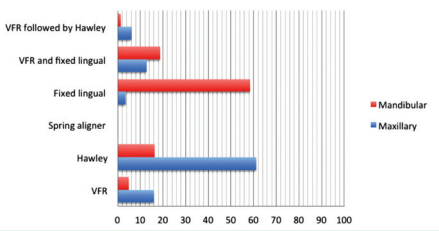

Frequency of maxillary and mandibular retainer use by type. VFR - vacuum formed retainers

Al-Jewair et al identify the retention protocols practiced by orthodontists in Saudi Arabia, and the factors affecting retainer choice. One hundred and sixty-seven (13.9%) responses were received during the study period. The results showed predominant use of Hawley in the maxillary arch (61.3%), and fixed lingual in the mandibular arch (58.5%). Approximately 90.3% recommended full-time maxillary removable retainer wear. Authors conclude that Hawley in the maxilla, and fixed lingual in the mandible were the most common retention protocols prescribed. Lifetime retention was the most common choice for participants who used removable retainers, especially when extractions were carried out.

see page 895

CASE REPORT

Bilateral combined laryngocele

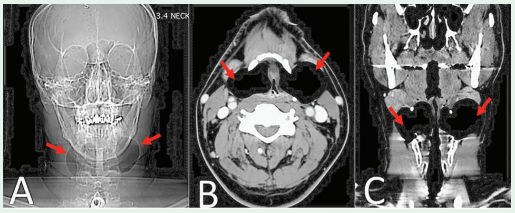

Image showing A) a plain soft tissue x-ray of the neck showing the shadow of the bilateral laryngocele. B) axial and C) coronal CT scan section of larynx confirmed bilateral combined laryngocele. Red arrows points to the laryngoceles

Suqati et al presents a 57-year-old, male patient presented with hoarseness, shortness of breath, and bilateral neck mass for 3 months. There was no history of fever, night sweats, weight loss, loss of appetite, fatigue, or head and neck cancer. He has been a heavy smoker (2 packs per day) for 40 years. He is a type-II diabetic, but using insulin and has history of cervical tuberculous lymphadenopathy 20 years ago, treated with triple medication for 9 months. Examination showed that he has a moderate stridor. Neck examination showed bilateral neck mass, mobile, non-tender, and soft, not attached to skin, or underlying tissue. His plain soft tissue neck x-ray and CT scan confirmed bilateral laryngoceles. The authors conclude that although combined laryngocele is rare, it should still be remembered in the differential diagnosis of upper airway problems, alongside the importance of endoscopy and imaging in reaching a definitive diagnosis in such cases.

see page 902