

# Recurrent venous thrombosis in a patient with Ebstein's anomaly

Deema A. Gashgarey, MBBS, Hazza A. Alzahrani, MD, Sultan S. Alfadl, MBBS, Sultan A. Alsobayeg, MBBS.

## ABSTRACT

نُوقِث في هذه الورقة البحثية حالة مرضية لرجل في السابعة والعشرين من العمر يعاني من تشوه إيشتاين الخلقى ولديه تاريخ مرضي بتجلطات وريدية متكررة غير معروفة السبب على الرغم من تناوله كمية كافية من مسيلات الدم. حالات التجلطات الوريدية لم تتكرر بعد التدخل الجراحي لتصحيح تشوه إيشتاين الخلقى. هذه الحالة المرضية تُبين لنا علاقة محتملة بين وجود تشوه إيشتاين الخلقى وتسببه في تجلطات دموية متكررة عن طريق مقاومة تدفق الدم في أوردة الجسم.

Herein, we report a case of a 27-year-old man with Ebstein's anomaly and a history of unexplained recurrent venous thrombosis despite adequate anticoagulation. After surgical correction of the Ebstein's anomaly, the venous thromboembolic events did not recur. This case demonstrates the possible etiopathogenesis of Ebstein's anomaly in causing recurrent venous thromboembolism, which is likely caused through impedance of venous blood flow. Our objective in presenting this particular case is to highlight the possible association between Ebstein's anomaly and venous thrombosis.

*Saudi Med J* 2018; Vol. 39 (2): 209-212  
doi: 10.15537/smj.2018.2.21317

From the College of Medicine (Gashgarey, Alfadl, Alsobayeg), Alfaisal University, and Adult Hematology/ Hematopoietic Stem Cell Transplantation Section (Alzahrani), Oncology Center, King Faisal Specialist Hospital and Research Centre, Riyadh, Kingdom of Saudi Arabia.

Received 18th September 2017. Accepted 18th December 2017.

Address correspondence and reprint request to: Dr. Deema A. Gashgarey, College of Medicine, Alfaisal University, Riyadh, Kingdom of Saudi Arabia. E-mail: dgashgarey@alfaisal.edu  
ORCID ID: [orcid.org/0000-0002-2655-8809](https://orcid.org/0000-0002-2655-8809)

**Disclosure.** Authors have no conflict of interests and the work was not supported or funded by any drug company.

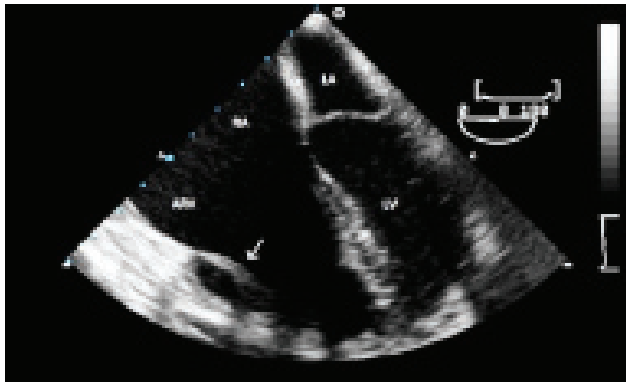
The proposed mechanisms for the pathogenesis of venous thrombosis are explained by the Virchow's triad, which consists of blood stasis, endothelial injury, and hypercoagulability.<sup>1</sup> The causes of venous thrombosis can be classified as hereditary, acquired, or mixed. Factor V Leiden mutation, prothrombin gene mutation, and defects in protein S, protein C, and/or anti-thrombin III are known to be common inherited risk factors of venous thrombosis. The common acquired risk factors of venous thrombosis include recent surgery, malignancy, trauma, pregnancy, immobilization, and previous thrombotic episodes.<sup>2</sup> Moreover, some vascular malformations are known to be risk factors for the development of deep vein thrombosis (DVT), such as Paget-Schroetter syndrome, May-Thurner syndrome, and Klippel-Trenaunay syndrome.<sup>3,4</sup> Ebstein's anomaly is a rare congenital heart disease that may be associated with right-to-left shunts that predisposes to paradoxical embolization.<sup>5</sup> Anticoagulant therapy is the initial treatment for venous thrombosis. Patients usually receive long-term anticoagulation therapy, such as warfarin or direct oral anticoagulants, which include dabigatran and rivaroxaban, to prevent recurrent thrombosis, embolism, and other late complications.<sup>6,7</sup> Our objective in presenting this particular case is to highlight the possible association between Ebstein's anomaly and venous thrombosis.

**Case Report. Patient information.** A 27-year-old man presented in 2003 to a local hospital in Jeddah, Kingdom of Saudi Arabia with a 3-month history of intractable vomiting preceded by a left-sided frontal headache that was compressing and pulsating, continuous, and decreasing after vomiting, with no focal neurological deficits (Table 1). There were no clear identifiable risk factors, as he was previously healthy and was not taking any medication or herbal treatments. He denied any intravenous drug abuse. There was no history of thrombophilia or similar presentation in the family. Brain magnetic resonance imaging at that time showed superior sagittal, bilateral transverse, and sigmoid

**Table 1** - Progress of the patient case from initial presentation to diagnosis, treatment and follow-up.

Dates	Summaries from initial and follow up visits	Relevant past medical history and interventions	
		Diagnostic testing	Interventions
8 <sup>th</sup> November 2003	Unprovoked cerebral sinus venous thrombosis diagnosed by brain MRI, managed with heparin followed by warfarin.		
24 <sup>th</sup> July 2004	Follow up visit	Blood investigations for thrombophilia were negative (Table 2)	No other intervention
20 <sup>th</sup> February 2005	DVT of the right leg	Doppler ultrasound	Treated with enoxaparin (1 mg/kg b.i.d.)
16 <sup>th</sup> April 2005	Follow up visit	Blood investigations showed an elevated platelet count of $479 \times 10^9/L$ . Bone marrow biopsy was normal.	No other intervention
16 <sup>th</sup> October 2005	Presented with abdominal distention and lower limb edema. She was admitted for management.  An incidental holosystolic murmur was found.	Blood investigations showed hemoglobin, 128 g/L; white blood cell count, $9.5 \times 10^9$ cells/L; platelets, $114 \times 10^9/L$ ; INR, 1.9; sodium, 134 mmol/L; albumin, 25 g/L; bilirubin, 89 $\mu\text{mol/L}$ ; alanine aminotransferase, normal.  Doppler ultrasound of the liver showed thrombosis of the hepatic veins and inferior vena cava  Transesophageal echocardiography showed Ebstein's anomaly	He was admitted for an angioplasty (carried out on 18 <sup>th</sup> October) of the inferior vena cava and right hepatic vein.  He resumed anticoagulation with 18 U/kg/h heparin IV, followed by warfarin (10 mg PO q.d.) and aspirin (100 mg PO q.d.).
16 <sup>th</sup> October 2006	Presented with shortness of breath and palpitations. He was admitted for corrective surgery of his Ebstein's anomaly.  Later during hospital course, he developed complete heart block	Routine pre-operative investigations	He was admitted for tricuspid valve replacement with mechanical valve (carried out on 18 <sup>th</sup> October)  Permanent pacemaker insertion (carried out on 30 <sup>th</sup> October)  Discharged on warfarin (4 mg PO q.d.) and aspirin (100 mg PO q.d.)

DVT - Deep vein thrombosis, PO - Oral, q.d. - Once daily, bid - Twice a day, IV - Intravenous, INR - International normalized ratio



**Figure 1** - Transesophageal echocardiogram (TEE) (4-chamber view, apex down) Ebstein's anomaly of the tricuspid valve is present. The septal leaflet is displaced apically, while the anterior tricuspid leaflet is elongated and tethered. (arrow) Absent posterior leaflet. ARV - atrialized right ventricle, RA - right atrium, LA - left atrium, LV - left ventricle

ductal venous sinus thrombosis. Initial thrombophilia workup, including complete blood count, coagulation profile, proteins C and S, antithrombin III, factor V

Leiden, lupus anticoagulant antibodies, and cardiolipin antibodies, were all normal.

Thus, he was diagnosed with unprovoked cerebral sinus venous thrombosis and was treated with heparin followed by warfarin for 2 years due to the severity of the event. He was referred to King Faisal Specialist Hospital and Research Centre for further management.

**Clinical findings.** In 2005, despite maintaining a therapeutic international normalized ratio (INR) level (2.5–3.5), he developed deep vein thrombosis in the right leg. Warfarin was discontinued, and he was treated with enoxaparin (1 mg/kg b.i.d.). Repeated thrombophilia workup showed negative results (Table 2).

In the course of his follow-up visits, he had a high platelet count that resolved on further follow-ups. Hence, bone marrow biopsy was carried out to determine any occult myeloproliferative neoplasms that can present with recurrent thrombosis. However, the result of the biopsy was normal. Eight months later, while on enoxaparin, he presented with abdominal distention and lower limb edema. Upon admission, his heart rate was 110 per minute. His blood pressure was

**Table 2** - Laboratory investigations for thrombophilia.

Test	Result
WBC	9.59 x 10 <sup>9</sup> /L
Hemoglobin	128 g/L
Platelets	114 x 10 <sup>9</sup> /L
PT	45.4 seconds
PTT	62.8 seconds
INR	3.7
Hemoglobin electrophoresis	Normal
Fibrinogen	3.50 g/L
Factor VIII activity	1.30 IU/mL
Factor IX	0.87 IU/mL
Protein C	0.73 IU/mL
Protein S	1.23 IU/mL
Factor V Leiden mutation	Negative
Prothrombin (G20210A) mutation	Negative
MTHFR C677T mutation	Negative
Homocysteine level	8 umol/L
Lupus profile	Negative
Antiphospholipid workup	Negative

WBC - White blood cells, PT - Prothrombin time, PTT - Partial thromboplastin time, INR - International normalized ratio, MTHFR - Methylene tetrahydrofolate reductase

117/78 mmHg, and his oxygen saturation in room air was 97%. His jugular venous pressure was elevated, with a prominent V-wave. First and second heart sounds were normal, and there was a loud holosystolic murmur at the left sternal border. The abdomen was distended, with large ascites and hepatomegaly, measuring 6 cm below the right costal margin. The rest of the examination was unremarkable.

Laboratory investigations during his hospital stay showed the following: hemoglobin, 128 g/L; white blood cell count, 9.5 x 10<sup>9</sup> cells/L; platelets, 114 x 10<sup>9</sup>/L; INR, 1.9; sodium, 134 mmol/L; albumin, 25 g/L; bilirubin, 89 umol/L; alanine aminotransferase, normal. The anti-Xa levels were not checked at the time because he had normal kidney function and was compliant with treatment.

**Diagnostic assessment.** He was diagnosed using Doppler ultrasound with Budd-Chiari syndrome. Moreover, because of the incidental finding of a murmur, he underwent echocardiographic evaluation and was diagnosed with Ebstein's anomaly and severe tricuspid regurgitation, with no evidence of atrial septal defect or patent foramen ovale (Figure 1).

**Therapeutic intervention.** He was successfully treated by angioplasty of the inferior vena cava and right hepatic vein. Anticoagulation was resumed with 18 U/kg/h heparin IV, followed by warfarin (10 mg PO q.d.) and aspirin (100 mg PO q.d.). A multidisciplinary

team decided to postpone any corrective cardiac surgery until the venous thromboembolic events (VTEs) were controlled.

A year later, he started complaining of shortness of breath and palpitations, which were affecting his daily activities. Consequently, he underwent tricuspid valve replacement with mechanical valve, which was complicated by complete heart block; thus, he underwent a permanent pacemaker insertion. The patient was maintained on warfarin (4 mg PO q.d.) and aspirin (100 mg PO q.d.) after discharge.

**Follow-up and outcomes.** Currently, 12 years after surgery, he remains asymptomatic and has no symptoms of recurrent VTE. He is maintained on warfarin (4 mg PO q.d.) and aspirin (100 mg PO q.d.) and undergoes regular follow-up for both cardiac and hematological conditions.

**Discussion.** Ebstein's anomaly is a rare congenital heart disease characterized by the downward displacement of the tricuspid valve leaflets into the right ventricle of the heart, resulting in atrialization of the right ventricle. Clinical presentation usually varies depending on the severity of the disease, ranging from no symptoms to severe clinical manifestations. Common associations of Ebstein's anomaly include interatrial communication, patent foramen ovale, ventricular septal defect, and distal right ventricle anomalies. It can be complicated by arrhythmias, severe cyanosis, heart failure, and death.<sup>8</sup> A common complication of Ebstein's anomaly in adults includes paradoxical embolism, which is an originally venous thrombus that transverses through a right-to-left shunt and enters the systemic circulation.<sup>5</sup> Our case demonstrates the rare association of Ebstein's anomaly with pure, recurrent venous thrombosis in the absence of a right-to-left shunt. Despite the administration of different, full-dose anticoagulant therapy, this patient still had recurrent VTE. The fact that his recurrent VTE totally disappeared after the surgical repair of the Ebstein's anomaly possibly suggests an association of the recurrent VTEs resulting from chronic venous stasis due to this cardiac anomaly. We reviewed the literature to try to identify this rare association, however; we only found one case in which Viallefont et al<sup>10</sup> reported a case of retinal vein thrombosis in association with Ebstein's anomaly.

Venous hepatic congestion can occur with Ebstein's anomaly, leading to the development of Budd-Chiari syndrome.<sup>9</sup> On the contrary, cerebral congestion and lower extremity venous congestion are not usually expected to occur in such patients.

In conclusion, Ebstein's anomaly is a rare disorder that can result in paradoxical embolisms when associated with right-to-left shunts. Venous stasis in patients with Ebstein's anomaly with tricuspid regurgitation may be a predisposing factor for VTE. Therefore, physicians caring for patients with such an anomaly should be aware of this rare association. In addition, patients presenting with recurrent unexplained thrombosis should have careful clinical evaluation and may require objective cardiac evaluation to rule out cardiovascular anomalies, as clinically indicated.

**Acknowledgment.** *The authors would like to thank Dr. Mohammed Alamri from the Heart Centre in King Faisal Specialist Hospital & Research Centre for reviewing the transesophageal echocardiography (TEE) figure.*

## References

1. Mackman, N. New insights into the mechanisms of venous thrombosis. *J Clin Invest* 2012; 122: 3368-3368.
2. Lijfering WM, Rosendaal FR, Cannegieter SC. Risk factors for venous thrombosis - current understanding from an epidemiological point of view. *Br J Haematol* 2010; 149: 824-833.
3. Sepúlveda P, Zavala A, Zúñiga P. Factors associated with thrombotic complications in pediatric patients with vascular malformations. *J Pediatr Surg* 2017; 52: 400-404.
4. Ibrahim W, Al Safran Z, Hasan H, Zeid WA. Endovascular Management of May-Thurner Syndrome. *Ann Vasc Dis* 2012; 5: 217-221.
5. LI J, Ma J, Yan Z, Cheng D, Chang L, Zhang H, et al. Acute arterial embolism of left lower extremity caused by paradoxical embolism in Ebstein's anomaly: A case report. *Medicine (Baltimore)* 2017; 96: e5901.
6. Barnes GD, Ageno W, Ansell J, Kaatz S; Subcommittee on the Control of Anticoagulation of the International Society on Thrombosis and Haemostasis. Recommendation on the nomenclature for oral anticoagulants: communication from the SSC of the ISTH. *J Thromb Haemost* 2015; 13: 1154-1156.
7. Kearon C, Akl EA, Comerota AJ, Prandoni P, Bounameaux H, Goldhaber SZ, et al. Antithrombotic therapy for VTE disease: Antithrombotic Therapy and Prevention of Thrombosis, 9th ed: American College of Chest Physicians Evidence-Based Clinical Practice Guidelines. *Chest* 2012; 141: e419S-e496S.
8. Geerdink L, Kapusta L. Dealing with Ebstein's anomaly. *Cardiol Young* 2013; 24: 191-200.
9. Asrani S, Asrani N, Freese D, Phillips S, Warnes C, Heimbach J, et al. Congenital heart disease and the liver. *Hepatology* 2012; 56: 1160-1169.
10. Viallefont H, Latour H, Puech P, Boudet C. [Bilateral thrombosis of the retinal veins associated with Ebstein's disease]. *Bull Soc Ophthalmol Fr* 1968; 68: 380-382. French

## Copyright

Whenever a manuscript contains material (tables, figures, etc.) which is protected by copyright (previously published), it is the obligation of the author to obtain written permission from the holder of the copyright (usually the publisher) to reproduce the material in Saudi Medical Journal. This also applies if the material is the authors own work. Please submit copies of the material from the source in which it was first published.