Clinicopathological and prognostic significance of androgen receptor overexpression in colorectal cancer

Experience from Al-Madinah Al-Munawarah, Saudi Arabia

Abdulkader M. Albasri, *MBBCh, PhD,* ***Mohammed A. Elkablawy,*** *MSc, PhD.*

ABSTRACT

الأهداف: دراسة علاقة زيادة مستوى بروتين مستقبل الأندروجين على الخصائص الاكلينيكية والباثولوجية لدى المرضى المصابين بسرطان القولون والمستقيم (CRC).

الطريقة: تم صبغ 324 حالة سرطان القولون والمستقيم بصبغة مستقبل الأندروجين للمرضى الذين تم تشخيصهم في قسم علم الامراض بمستشفى الملك فهد، المدينة المنورة، المملكة العربية السعودية في الفترة من يناير 2006م إلى ديسمبر 2017م.

النتائج: لم تلاحظ أي زيادة لمستوى البروتين في أي من الأنسجة الطبيعية السليمة. أما في حالات الأورام الحميدة، فقد وجد زيادة لمستوى البروتين في 40% من الحالات. في حالات السرطان لوحظ زيادة في مستوى البروتين في 36.4% من الحالات. لم تلاحظ أي علاقة إحصائية بين زيادة مستوى البروتين وبين جنس المرضى وأعمارهم ونوع الورم ومكانه. ومع ذلك فقد لوحظ أن هناك علاقة إحصائية بين زيادة مستوى البروتين وحجم الورم (p=0.026) ودرجة تباين الورم (p=0.047) ومستويات تطور الورم المتقدمة (p=0.043) وانتشاره في العقد اللمفاوية (p=0.018) والأوعية اللمفاوية (p=0.018) وفي باقي أجزاء الجسم (p=0.049). وقد أثبتت الدراسة أيضا أن زيادة مستوى بروتين مستقبل الأندروجين تعتبر من مؤشرات الإنذارات المستقلة الهامة والتي تؤثر سلبيا على حياة المرضى المصابين بسرطان القولون والمستقيم (p=0.002)، مما يشير إلى إمكانية استخدامه كعامل مهم للتنبؤ بتطور سرطان القولون والمستقيم.

الخاتمة: انتهت الدراسة إلى العلاقة بين زيادة مستوى بروتين مستقبل الاندروجين والمؤشرات السلبية على حياة المرضى المصابين بسرطان القولون والمستقيم.

Objectives: To examine the androgen receptor (AR) status in colorectal cancer (CRC) patients by the immunohistochemical method and to correlate the findings with all available clinicopathological parameters of prognostic significance.

Methods: Archival tumor samples were studied using immunohistochemistry for AR expression in 324 patients with CRC. Patients were diagnosed at the Pathology Department at a tertiary care Hospital, Al-Madinah Al-Munawarah, Saudi Arabia, between January 2006 and December 2017.

Results: There is a complete lack of AR expression in normal colonic mucosa; however, AR was expressed in 16 cases (40%) of colorectal adenoma. In CRC, AR expression was high in 118 cases (36.4%). There were no significant correlations between AR expression and gender, age, tumor histologic type, and tumor location. However, AR expression revealed a significant correlation with tumor size (p=0.026), tumor differentiation (p=0.047), American Joint Committee on Cancer (AJCC) staging (p=0.043), lymph node positivity (p=0.018), lymphovascular invasion (p=0.018), and distant metastasis (p=0.049). In univariate Kaplan-Meier survival analysis, there was a significant (p=0.002) difference in overall survival between AR positive and negative tumors in favor of the latter. In multivariate (COX) models, high AR expression (p=0.002), AJCC (p<0.001), and lymphovascular invasion (p<0.001) were the only significant independent prognostic indicators of overall survival in CRC.

Conlusion: Our study showed that the patients with higher AR expression had a significantly poorer survival rate, AR expression had the potential to be a prognostic marker of CRC.

Saudi Med J 2019; Vol. 40 (9): 893-900
doi: 10.15537/smj.2019.9.24204

From the Department of Pathology (Albasri, Elkablawy), Taibah University, Al-Madinah Al-Munawwarah, Kingdom of Saudi Arabia; and from the Department of Pathology (Elkablawy), Menofia University, Menofia, Egypt.

Received 12th February 2019. Accepted 11th July 2019.

Address correspondence and reprint request to: Dr. Abdulkader M. Albasri, Associate Professor, Pathology Department, Faculty of Medicine, Taibah University, Al-Madinah Al-Munawarah, Kingdom of Saudi Arabia. E-mail: abdbasri@hotmail.com
ORCID ID: https://orcid.org/0000-0002-1824-4025

OPEN ACCESS

The androgen receptor (AR) belongs to the group of nuclear receptors and functions as a transcription factor that binds to DNA and thus regulates gene expression. Androgens (mainly testosterone) are hormones that bind to AR and are essential for the development of the male reproductive system and secondary sexual characteristics.[1] Some of the non-reproductive organ tissues of both males and females are also subject to androgen regulation.[2] Due to its role in the development of the prostate, AR has been used as a primary target of endocrine therapy in prostate cancer (CaP). Inhibition of AR signaling has been reported to have major benefits for patients with CaP.[3] Androgen receptor has been studied in detailed recently in relation to CaP from a molecular perspective[4] as well as its expression in patients with diabetes,[5] the role of stromal AR in the development and progression of CaP,[6] and in drug discovery.[7] Androgen receptor has also been thoroughly studied for its role in breast carcinoma;[8,9] as well as in urothelial/bladder carcinoma.[10,11] Moreover, some studies have addressed the role of AR in different organs and systems (example: penile carcinoma),[12] the cardiovascular system,[13] and fibrosarcoma.[14] Similarly, the role of androgens has also been studied in the gastrointestinal tract and colorectal carcinoma (CRC) by a number of studies.[15,16]

The aim of this study was to examine the AR status in CRC patients by the immune-histochemical method and to correlate the findings with all available clinicopathological parameters of prognostic significance.

Methods. This retrospective study involved 324 cases of CRC diagnosed at the Department of Pathology, King Fahad Hospital, Al Madinah Al Munawarah, Saudi Arabia between January 2006 and December 2017. All clinical and histopathological data of the patients were collected from the patients' medical records and included gender, age, tumor type, size, site, grade, lymphovascular invasion, lymph nodes status, metastasis stage, and the American Joint Committee on Cancer (AJCC) stages of CRC. Clinical and pathological data of patients are shown in **Table 1.** Forty cases of colorectal adenoma and 20 normal colonic mucosa cases were used as controls. The inclusion criteria was histologically confirmed invasive CRC cases, including CRCs cases with distant metastasis, whereas the exclusion criteria were in-situ lesions, recurrences, benign lesions, and metastatic lesions. All total colectomies, hemi-colectomies, and excision specimens were included in the analysis. The study did not involve patients' personal information or any implication upon the management. Therefore, according to the principles of the Helsinki Declaration, no ethical approval was mandatory for this study.

Immunohistochemical procedures. Tissue cores were extracted from archival blocks of the primary CRC and used in the construction of tissue miniarrays (TmAs) using Elkablawy and Albasri's[17] modified TmA technique as follows: a semiautomatic metal puncher with a 5 mm punch tip was used as a TmA manual kit to punch and extract the tissue cores from prewarmed paraffin blocks from the main donor tissue blocks. The cores were manually transferred, organized, and

Disclosure. Authors have no conflict of interests, and the work was not supported or funded by any drug company.

Table 1 - The clinicopathological features of 324 colorectal carcinoma cases.

Variables	n	(%)
Age (years)		
<40	177	(54.6)
≥40	147	(45.4)
Gender		
Female	128	(39.5)
Male	196	(60.5)
Tumor site		
Colon	168	(51.9)
Rectum	156	(48.1)
Tumor size		
<4cm	52	(16.0)
≥4cm	272	(84.0)
Tumor type		
Adenocarcinoma	279	(86.1)
Mucinous adenocarcinoma	45	(13.9)
Tumor differentiation		
Well	49	(15.1)
Moderate	260	(80.2)
Poor	15	(4.7)
Lymph node		
Negative	179	(55.2)
Positive	145	(44.8)
Lymphovascular invasion		
Negative	179	(55.2)
Positive	145	(44.8)
Distant metastasis		
Negative	281	(86.7)
Positive	43	(13.3)
AJCC		
I	34	(10.5)
II	145	(44.7)
III	102	(31.5)
IV	43	(13.3)

attached to a standard block mold with glue and filled with liquid paraffin to build TmA blocks. We then cut 4 micrometer-thick sections of tissue from the TmA blocks, mounted on poly-l-lysine-coated slides and subjected them to immunohistochemistry (IHC) using the Avidin Biotin detection system, as directed by manufacturer guidelines. Immunohistochemistry was carried out using an automatic system (Bench-Mark XT; Ventana Medical Systems, Inc., Tucson, AZ, USA). The antibody used was a rabbit anti-AR monoclonal antibody (diluted 1:100 in blocking solution; Clone SP107, Ventana Inc., Tucson, AZ, USA). A sample of normal prostatic tissue was used as a positive control for the anti-AR antibody. Negative controls were accomplished by replacing the primary antibody with serum.

Interpretation of immunohistochemical staining. Cells were considered positive for AR when distinct nuclear yellow to brown staining was identified. The immunostaining was reviewed independently, and the average score was taken. The level of AR overexpression was calculated by combining an estimate of the percentage of immunoreactive cells (quantity score) with an estimate of the staining intensity (staining intensity score) as follows. No staining was scored as 0; 1-10% of cells with positive staining were scored as 1; 10-50% as 2; 50-70% as 3; and 70-100% as 4. Staining intensity was rated on a scale of 0 to 3 as follows: 0=negative (no staining); 1=weak; 2=moderate; and 3=strong. The percentage and intensity scores were multiplied to produce a weighted score (WS) for each specimen. The final expression score was expressed as follows: '-' for a WS of 0; '+' for WS 1-3; '++' for WS 4-6; and '+++' for WS > 6. For statistical analysis, the cases that scored as '-' and '+' (low WS) were combined and then compared to the cases that scored as '++' and '+++' (high WS).

Statistical analysis. Statistical analyses were performed using the Statistical Package for Social Sciences version 22.0 for Windows (IBM Corp, Armonk, NY, USA). Frequency tables were analyzed using the Chi-square and Fisher's exact tests to determine the association between the AR expression and the variable clinicopathological parameters. The cumulative patient survival was assessed by the Kaplan-Meier method. Finally, the long-rank test was used for comparison of the survival curves. In order to assess the value of AR as an independent factor independently associated with survival, multivariate survival analysis was performed using the Cox proportional hazards regression model controlling for confounding by the following variables: gender, age, tumor type, size, site, grade, lymphovascular invasion, lymph nodes status, metastasis stage, and the AJCC stages. In all tests, a p value of ≤0.05 was regarded as statistically significant.

Results. *Androgen receptor expression profiles*. A complete lack of AR expression was shown in normal colonic mucosa; however, AR was expressed in 16 cases (40%) of colorectal adenoma. In CRC, AR expression was high in 118 cases (36.4%) and low in 206 cases (63.6%) (**Figure 1**).

Expression of androgen receptor and its correlation with clinicopathological variables. No significant correlations were shown between AR expression and gender, age, tumor histologic type, or tumor location. However, AR expression revealed a significant correlation with tumor size (p=0.026), tumor differentiation (p=0.047), and AJCC staging (p=0.043), as well as metastatic parameters (exmaple: lymph node positivity; p=0.018), lymphovascular invasion (p=0.018), and distant metastasis (p=0.049). The relation of AR expression to clinicopathological variables as summarized in **Table 2**.

The significant features associated with survival for the patients are summarized in **Table 3**. The survival curve for the AR immunoprofile is provided in **Figure 2**. Significantly short survival was observed in patients with high AR overexpression compared to patients with low AR overexpression (p=0.002). High AR expression (p=0.002), AJCC classification (p<0.001), and lymphovascular invasion (p<0.001) were the only significant independent prognostic indicators, as calculated by multivariate analysis of the Cox regression model.

Discussion. Androgen receptor is a receptor belonging to the group of nuclear receptors. Androgens are essential for the development of the male reproductive system and secondary sexual characteristics[1] and morphogenesis of male reproductive organs (the epididymis, seminal vesicle, prostate, and penis) are determined by androgens during embryogenesis.[18] These androgen-dependent signals and downstream events are crucial not only for developmental processes but also processes of diseases, such as hypospadias and CaP.[18] Aberrant AR activity is promoted by irregularities of the binding partner or mutations, which can present as a number of clinical manifestations that include androgen insensitivity syndrome as well as CaP. In the latter case, treatment generally involves deprivation therapies interfering with AR action.[19] Due to the main function of androgens in the development and growth of genital organs, including both primary and secondary sexual

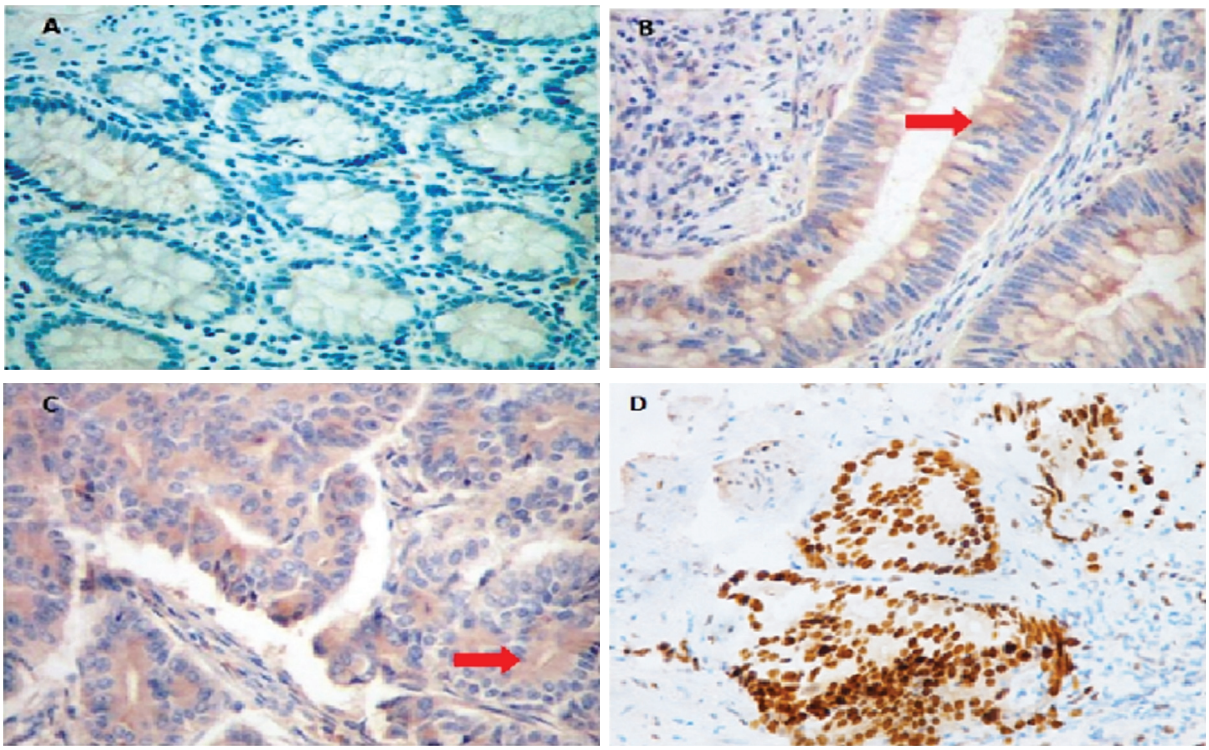

Figure 1 - Photomicrograph of different patterns of androgen receptor (AR) expression by immunohistochemistry in **A**) normal colonic mucosa showing a negative expression of AR, **B**) colorectal adenoma showing cytoplasmic expression of AR in the tumor cells, **C**) Colorectal carcinoma showing intense cytoplasmic expression of AR in tumor cells, and **D**) a control sample from prostatic adenocarcinoma showing intense nuclear expression of AR in the tumor cells. Arrows indicate cytoplasmic expression of AR.

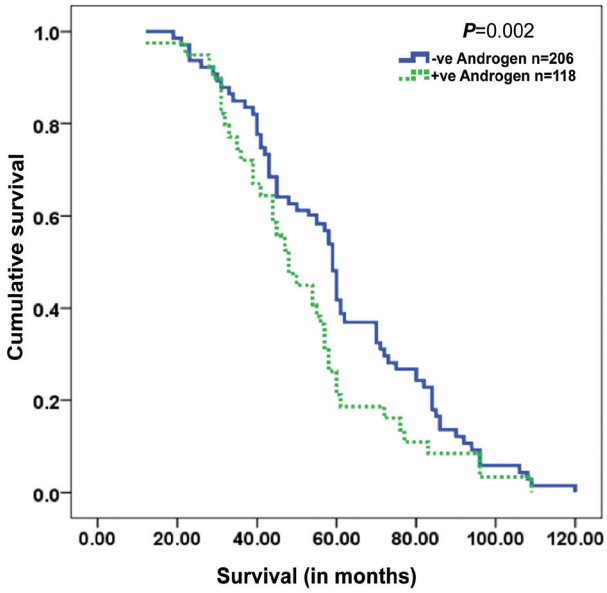

Figure 2 - Kaplan- Meier survival curves showing significant overall lower survival functions for high AR expression in colorectal cancer cases.

properties, AR has been extensively studied in a number of related disorders to block the effects of androgens, especially neoplasia, such as urothelial cancer,[20-24] penile carcinoma,[12] as well as CaP.[9] Various results have shown that AR has distinct and contrasting roles in each cell type within many hormone-related tumors. Androgen receptor has been found to be a stimulator in bladder, kidney, and lung metastases and as a suppressor in prostate and liver metastases.[25]

Extensive work on AR has been carried out particularly concerning CaP. Androgen receptor has been used as a primary target of endocrine therapy in CaP.[26] A number of excellent reviews have been published in the literature regarding the role of AR in CaP.[14,16] Overexpression of AR in CaP has also been recently studied in diabetes mellitus type 2, due to reported poor survival of CaP diabetic patients.[5] The inhibition of AR signaling has been shown to have major benefits for patients with CaP.[3]

As mentioned, AR has also been significantly studied in urothelial cancers, as these are more common in

Table 2 - Relation of androgen receptor immunoexpression to clinicopathological parameters.

Variable	Low AR	High AR	*P*-value
Age (year)			0.354
<40	117	60	
≥40	89	58	
Gender			0.724
Female	83	45	
Male	123	73	
Tumor site			0.729
Colon	105	63	
Rectum	101	55	
Tumor size			0.026
<4cm	26	26	
≥4cm	180	92	
Tumor type			0.619
Adenocarcinoma	179	100	
Mucinous adenocarcinoma	27	18	
Tumor differentiation			0.047
Well	27	22	
Moderate	173	87	
Poor	6	9	
Lymph node			0.018
Negative	124	55	
Positive	82	63	
Lymphovascular invasion			0.018
Negative	124	55	
Positive	82	63	
Distant metastasis			0.049
Negative	184	97	
Positive	22	21	
AJCC			0.043
I	21	13	
II	103	42	
III	60	42	
IV	22	21	

AR - androgen receptor, AJCC - American Joint Committee on Cancer stage

Table 3 - Test statistics for equality of survival distribution for prognostic factors examined in 324 colorectal carcinomas. A multivariate-Cox proportional hazards regression approach to the overall survival.

Clinicopathological factor	Multivariate analysis		
	HR	95% CI	*P*-value
AJCC stage	2.512	2.051-2.924	<0.000
Lymph node stage	1.084	0.709-1.318	0.202
Metastasis stage	0.961	0.725-1.283	0.484
Lymphovascular invasion	2.961	2.709-3.118	<0.000
Histological tumor grade	0.815	0.552-1.187	0.575
Tumor size	0.751	0.515-0.914	0.633
Tumor site	0.561	0.213-0.881	0.665
Tumor type	0.353	0.191-0.565	0.783
Age	0.508	0.361-0.716	0.715
Gender	0.114	0.097-0.121	0.906
Immunostaining			
AR immunostaining	1.578	1.119-1.561	0.002

HR - hazard ratio, CI - confidence interval

males than in females, and preclinical evidence points toward correlation of the activation of AR in urothelial cancers.[10,20] Thus, the expression of AR in non-muscle-invasive bladder cancer was studied, which predicted the preventive effect of androgen deprivation therapy on tumor recurrence.[23]

Iacopetta et al,[27] from Italy, published a detailed review on the role of AR in breast carcinoma in light of recent study indicating an emerging hormonal target in breast cancer that has clinical benefits in both estrogen receptor (ER) positive and ER negative tumors. Due to failure of hormonal and herceptin therapies in triple negative breast cancers (TNBC), a special interest has been shown in anti-androgen therapy in the AR positive TNBC cases. Safarpour et al[28] found more than one-third (36%) AR positive cases in 50 TNBC cases and have thus recommended a routine assessment of AR in TNBC. Although some scientists have reported that AR expression predicts a decreased survival in the early stages of TNBC,[29] phase 2 clinical trials on anti-AR therapy have shown benefits to some degree in AR positive TNBC.[30,31]

The latest GLOBOCAN 2018 update reported that the world cancer burden was 18.1 million new cases and 9.6 million cancer deaths in 2018.[32] Colorectal cancer is one of the leading cancers in the world today, fourth in the rank of incidence rate; it is second only to lung cancer in cancer mortality rates.[33] Colorectal cancer incidence appears to be lower in developing Asian and African countries as compared to the developed countries, and the KSA belongs to a low CRC incidence region. However, CRC is still the second most common cancer, after, according to the latest Saudi cancer registry.[32] According to the latest regional hospital pathology-based study from Madinah, CRC was diagnosed in an advanced stage in the majority of case.[34]

Due to the high prevalence of CRC in the western world, as well as globally, extensive study is in progress to learn more on CRC regarding its prevention, diagnosis, and management. Some of the latest studies focused on improved detection methodologies (stool analysis for genetic changes), prediction of recurrence (identification of genes associated with growth and spread), immunotherapy, *BRAF* mutation target therapies, new drugs, and palliative care.[35]

For example, a UK-based study of a large number of patients (n=2624) analyzed the ploidy and digital tumor-stromal morphometry. This study concluded that these novel biomarkers could identify risks for recurrence and mortality in CRC patient sub-populations and could be helpful in the choice of adjuvant therapy of these CRC patients. This study was based on the methodology

of automated digital imaging systems and analysis of microsatellite instability of DNA extracted from paraffin-embedded tumor tissue.[36] However, despite these advanced techniques and markers that have been studied recently, comparatively less study was found in relation to hospital and patient-based studies for AR in the western world, and no data was available on AR in the CRC patient population in this country and region.

To find some study on hormones and their receptor status in CRC-including ER, PR, steroid, and glucocorticoid receptors-research had to be examined from almost half a century ago. In 1979, Alford et al[37] from the USA, studied only 33 patients and concluded that some large bowel cancers might be endocrine dependent. They found AR in approximately 26% of the cases. In 1980, Mehta et al[38] worked on chemically induced CRC in rat models and suggested that gender steroids were involved in carcinogen-induced colon tumorigenesis and that the action was mediated by their association with gender steroid-specific receptors. Similarly, Izbicki et al[39] worked on experimentally induced colon carcinogenesis in rat models, albeit specifically studied the AR. They concluded that the carcinogenesis of CRC was only mildly affected by any manipulation of androgens. Scientists from M.D. Anderson Cancer Center, USA, working on colon cancer cell lines suggested that estrogen and glucocorticoid hormones might play an important role in the growth of colon carcinoma cells; in contrast, androgen and progesterone hormones appeared to be less relevant in CRC carcinogenesis and growth.[40]

The first significantly large patient-based study on AR was published from France in 1991. In a hospital patient cohort of 94 patients, they found AR in 98% of normal large bowel mucosa and 96% of CRC mucosa.[41] However, they commented that the elevated AR in normal mucosa was not related to any known function of androgens in the digestive tract. Additionally, study from Brazil found complete negativity of AR in both normal and tumor mucosa. This study was only 22 CRC cases, and the methodology performed was a charcoal dextran assay.[42]

In contrast, this present study included 324 CRC cases, along with 40 cases of colorectal adenoma and 20 cases of normal mucosa as controls. A complete absence of AR was found in the normal mucosa; however, 40% of cases of adenoma revealed 40% AR positivity. Some level of positivity was found in all the CRC cases (example: high activity in approximately one-third of the cases and low activity in the remaining two-thirds).

These results are in the middle of almost all-positive AR results by Meggough et al[41] from France and Brentani et al[42] from Brazil. Explaining these contrasting results is difficult; however, the possibilities include the differences in methodologies, such as hybrid ligand methodology for AR measurement[43] and charcoal dextran assay by Brentani et al[42.] However, recent study utilizing the latest methodologies at genetic levels in vivo and vitro raises the possibility of different types of AR (membranous and cytoplasmic types).[39] The membranous type of AR appears to trigger a strong apoptotic response.[44] This same group of scientists, extending the study in the field of AR in CRC, have concluded that AR activation inhibits both in vitro and in vivo survival signals.[45] These differences have also been addressed on the basis of altered expression of AR isoforms in CRC.[46]

Regarding the correlation of AR expression and various clinicopathological parameters in this present study, a significant correlation of AR expression was found with tumor size, differentiation, AJCC stages, and metastatic parameters, raising the possibility that AR positivity in CRC is an indicator of aggressive behavior of the tumor as well as its metastatic potential. Unfortunately, no study of this type and caliber could be found in recent or remote literature after extensive study. Similarly, a significantly short survival was found in patients with high AR overexpression; the independent prognostic markers were found to be high AR expression, AJCC stages, and lymphovascular invasion.

In conclusion, AR expression was performed in a large cohort of CRC patients, utilizing an immunohistochemical technique on microarray samples. Significant correlation of high AR expression was found with a number of clinicopathological and prognostic parameters, including short survival. Similar studies should be performed to validate these results. These studies could help scientists to develop better therapeutic approaches to target AR-mediated signals and better fight AR-sensitive cancers.

Acknowledgment. *We gratefully acknowledge the Deanship of Scientific Research, Taibah University, Al Madinah Al Munawarah, Kingdom of Saudi Arabia, for their constant encouragement and support. We would also like to thank Scribendi (https://www.scribendi.com) for the English Language editing of the manuscript.*

References

1. Davey RA, Grossmann M. Androgen receptor structure, function and biology: from bench to bedside. ***Clin Biochem Rev*** 2016; 37: 3-15.

2. Pihlajamaa P, SahuB, Jänne OA. Determinants of Receptor- and Tissue-Specific Actions in Androgen Signaling. ***Endocr Rev*** 2015; 36: 357-384.
3. Modi PK, Faiena I, Kim IY. Androgen receptor (chapter 3). Prostate cancer (second edition). Science and clinical practice; 2016: 21-28.
4. Hu J, Wang G, Sun T. Dissecting the roles of the androgen receptor in prostate cancer from molecular perspectives. ***Tumour Biol*** 2017: 39: 1010428317692259.
5. Lutz SZ, JörgHennenlotter J, Scharpf MO, Sailer C, Fritsche L, Schmid V, et al. Androgen receptor overexpression in prostate cancer in type 2 diabetes. ***Mol Metab*** 2018; 8: 158-166.
6. Leach DA, Buchanan G. Stromal androgen receptor in prostate cancer development and progression. ***Cancers*** 2017; 9: 1-24.
7. Liu YX, Zhang KJ, Tang LL. Clinical significance of androgen receptor expression in triple negative breast cancer; an immunohistochemistry study. ***Oncol Lett*** 2018; 15: 10008-10016.
8. Astvatsaturyan K, Yue Y, Walts AE, Bose S. Androgen receptor positive triple negative breast cancer: clinicopathologic, prognostic, and predictive features. ***PLoS One*** 2018; 13: e0197827.
9. Tan MH, Li J, Xu HE, Melcher K, Yong EL. Androgen receptor: structure, role in prostate cancer and drug discovery. ***Acta Pharmacol Sinica*** 2015; 36: 3-23.
10. Inoue S, Mizushima T, Miyamoto H. Role of the androgen receptor in urothelial cancer. ***Mol Cell Endocrinol*** 2018; 465: 73-81.
11. Mizushima T, Tirador KA, Miyamoto H. Androgen receptor activation: a prospective therapeutic target for bladder cancer? ***Expert OpinTher Targets*** 2017; 21: 249-257.
12. Kuasne H, Barros-Filho MC, Marchi FA, Drigo SA, Scapulatempo-Neto C, Faria EF, et al. Nuclear loss and cytoplasmic expression of androgen receptor in penile carcinomas: role as a driver event and as a prognosis factor. ***Virchow Archiv*** 2018; 473: 607-614.
13. Lucas-Herald AK, Alves-Lopes R, Montezano AC, Ahmed SF, Touyz RM. Genomic and non-genomic effects of androgens in the cardiovascular system: clinical implications. ***Clin Sci (Lond)*** 2017; 131: 1405-1418.
14. Castoria G, Giovannelli P, Di Donato M, Hayashi R, Arra C, Appella E, et al. Targeting androgen receptor/SRC complex impairs the aggressive phenotype of human fibrosarcoma cells. ***PLoS One*** 2013; 8: e76899
15. Roshan MHK, Tambo A, Pace NP. The role of testosterone in colorectal carcinoma: pathomechanisms and open questions. ***EPMA J*** 2016; 7: 22.
16. Sukocheva OA, Li B, Due SL, Hussey DJ, Watson DI. Androgens and esophageal cancer: What do we know? ***World J Gastroenterol*** 2015; 21: 6146-6156.
17. Elkablawy MA, Albasri AM. High quality tissue miniarray technique using a conventional TV/radio telescopic antenna. ***Asian Pac J Cancer Prev*** 2015; 16: 1129-1133.
18. Matsushita S, Suzuki K, Murashima A, Kajioka D, Acebedo AR, Miyagawa S, et al. Regulation of masculinization: androgen signalling for external genitalia development. ***Nat Rev Urol*** 2018; 15: 358-368.
19. Bennett NC, Gardiner RA, Hooper JD, Johnson DW, Gobe GC. Molecular cell biology of androgen receptor signalling. ***Int J Biochem Cell Biol*** 2010; 42: 813-827.
20. Li P, Chen J, Miyamoto H. Androgen receptor signaling in bladder cancer. ***Cancers (Basel)*** 2017; 9: pii: E20.
21. Kang M, Ku JH. The role of androgen receptor signaling pathways in bladder cancer. ***Transl Cancer Res*** 2017; 6: S702-S707.
22. Chen J, Cui Y, Li P, Liu L, Li C, Zu X. Expression and clinical significance of androgen receptor in bladder cancer: A meta-analysis. ***Mol Clin Oncol*** 2017; 7: 919-927.
23. Izumi K, Ito Y, Miyamoto H, Miyoshi Y, Ota J, Moriyama M, et al. Expression of androgen receptor in non-muscle-invasive bladder cancer predicts the preventive effect of androgen deprivation therapy on tumor recurrence. ***Oncotarget*** 2016; 22: 14153-14160.
24. Lombard AP, Mudryj M. The emerging role of the androgen receptor in bladder cancer. ***Endocr Relat Cancer*** 2015; 22: R265-R277.
25. Chang C, Lee SO, Yeh S, Chang TM. Androgen receptor (AR) differential roles in hormone-related tumors including prostate, bladder, kidney, lung, breast and liver. ***Oncogene*** 2014; 33: 3225-3234.
26. Ahmed A, Ali S, Sarkar FH. Advances in androgen receptor targeted therapy for prostate cancer. ***J Cell Physiol*** 2014; 229: 271-276.
27. Iacopetta D, Rechoum Y, Fuqua SAW. The role of androgen receptor in breast cancer. ***Drug Discov Today Dis Mech*** 2012; 9 (1-2): e19-e27.
28. Safarpour D, Pakneshan S, Tavassoli FA. Androgen receptor (AR) expression in 400 breast carcinomas: is routine AR assessment justified? ***Am J Cancer Res*** 2014; 4: 353-368.
29. Choi JE, Kang SH, Lee SJ, Bae YK. Androgen receptor expression predicts decreased survival in early stage triple-negative breast cancer. ***Ann Surg Oncol*** 2015; 22: 82-89.
30. Gucalp A, Traina TA. Androgen receptor: is it a promising target? ***Ann Surg Oncol*** 2017; 24: 2876-2880.
31. Kono M, Fujii T, Lim B, Karuturi MS, Tripathy D, Ueno NT. Androgen receptor function and androgen receptor-targeted therapies in breast cancer. A Review. ***JAMA Oncol*** 2017; 3: 1266-1273.
32. World Health Organization. International Agency for Cancer research (IACR). 2018. [Updated 2019. Cited 31 December 2018]. Available from: https://www.iarc.fr/wpcontent/uploads/2018/09/pr263_E.pdf
33. Bray F, Ferlay J, Soerjomataram I, Siegel RL, Torre LA, Jemal A. Global cancer statistics 2018: GLOBOCAN estimates of incidence and mortality worldwide for 36 cancers in 185 countries. ***CA Cancer J Clin*** 2018; 68: 394-424.
34. Albasri A, Yosef H, Hussainy AS, Sultan SA, Alhujaily AS. Histopathological features of colorectal cancer in Al-Madinah region of Saudi Arabia: 8 years experience. ***Asian Pac J Cancer Prev*** 2014; 15: 3133-3137.
35. Cancer net. Colorectal cancer: latest research. 2018. [Updated 2019. Cited 17 January 2019]. Available from: https://www.cancer.net/cancer-types/colorectal-cancer/latest-research
36. Danielsen HE, Hveem TS, Domingo E, Pradhan M, Kleppe A, Syvertsen RA, et al. Prognostic markers for colorectal cancer: estimating ploidy and stroma. ***Ann Oncol*** 2018; 29: 616-623.
37. Alford TC, Do HM, Geelhoed GW, Tsangaris NT, Lippman ME. Steroid hormone receptors in human colon cancers. ***Cancer*** 1979; 43: 980-984.
38. Mehta RG, Fricks CM, Moon RC. Androgen receptors in chemically-induced colon carcinogenesis. ***Cancer*** 1980; 15: 1085-1089.

39. Izbicki JR, Wambach G, Hamilton SR, Harnisch E, Hogenschurz R, Izbicki W, et al. Androgen receptors in experimentally induced colon carcinogenesis. ***J Cancer Res Clin Oncol*** 1986; 112: 39-46.
40. Lointier P, Wildrick DM, Boman BM. The effects of steroid hormones on a human colon cancer cell line in vitro. ***Anticancer Res*** 1992; 12: 1327-1330.
41. Meggouh F, Lointier P, Pezet D, Saez S. Status of sex steroid hormone receptors in large bowel cancer. ***Cancer*** 1991; 67: 1964-1970.
42. Brentani MM, Liberato MH, Macedo TM, Habr-Gama A, Laudanna AA. Steroid receptors in Brazilian patients with large bowel cancer. ***Braz J Med Biol Res*** 1993; 26: 277-284.
43. Stebbings WS, Anderson E, Puddefoot JR, Farthing MJ, Vinson GP. A hybrid ligand method for androgen receptor measurement. ***J Steroid Bioche***m 1988; 31: 181-186.
44. Gu S, Papadopoulou N, Gehring EM, Nasir O, Dimas K, Bhavsar SK, et al. Functional membrane androgen receptors in colon tumors trigger pro-apoptotic responses in vitro and reduce drastically tumor incidence in vivo. ***Mol Cancer*** 2009; 8: 114.
45. Gu S, Papadopoulou N, Nasir O, Föller M, Alevizopoulos K, Lang F, et al. Activation of membrane androgen receptors in colon cancer inhibits the prosurvival signals akt/bad in vitro and in vivo and blocks migration via vinculin/actin signaling. ***Mol Med*** 2011; 17: 48-58.
46. Catalano MG, Pfeffer U, Raineri M, Ferro P, Curto A, Capuzzi P, et al. Altered expression of androgen-receptor isoforms in human colon-cancer tissues. ***Int J Cancer*** 2000; 86: 325-330.