

## REVIEW ARTICLE

### Efficacy of gluten- and casein-free diets on autism spectrum disorders in children

Alamri investigated the role of gluten- and casein-free diet (GCFD) on the management of autism spectrum disorders (ASD). In total, 9 randomized controlled trials were included (521 participants) with age range between 2 to 18 years. Four of these studies did not show a significant improvement regarding the symptoms of ASD. The rest of these studies (n=5) showed improvement in communication, stereotyped movements, aggressiveness, language, hyperactivity, tantrums, and signs of attention deficit hyperactivity disorder compared to control group. Hence, the data remains insufficient to support the use of GCFD to improve the symptoms of ASD in children. A retrospective case-control study of all patients diagnosed with the great arteries (TGA) between 1999 to 2016 at King Abdulaziz Medical City, Riyadh, Saudi Arabia. Age and gender-matched controls were selected. To assess potential risk factors and their effect on the development of TGA.

see page 1041

## ORIGINAL ARTICLES

### Risk factors for transposition of the great arteries in Saudi population

Variables/TGA type	Mean	SEM*	Median	Q1	Q3	P-value <sup>†</sup>
<b>Age at diagnosis</b>						0.002
Simple	83.19	32.11	6	2	16	
Complex	69.61	15.05	14	5	55	
<b>Age at surgery</b>						<0.001
Simple	121.1	40.61	14	9	28	
Complex	102.76	18.24	27	14	79	

\*Standard error of mean, †p-value for Mann-whitney test was reported

Distribution of age at diagnosis and at surgery between transposition of the great arteries (TGA) types

Alfarhan et al assess potential risk factors and their effect on the development of transposition of the great arteries (TGA). All patients diagnosed with TGA between 1999 to 2016 at King Abdulaziz Medical City, Riyadh, Saudi Arabia. Age and gender-matched controls were selected. A total of 206 patients with transposition of the great arteries were enrolled in the study. In the studied cases, consanguinity was found in 95 of cases, gestational diabetes was diagnosed in 36 mothers, and 35 had a confirmed family history of congenital heart disease. The authors revealed significant risk factors for the development of transposition of great arteries including first degree consanguineous marriages, gestational diabetes, family history of congenital cardiac anomalies, and increasing maternal age and parity.

see page 1054

### The current practice of using angiotensin-converting enzyme inhibitors and angiotensin II receptor blockers in diabetic hypertensive and non-hypertensive patients. Is there a room for vitamin D?

Factor	N	n (%)	P-value*
<b>Hospital</b>			0.046
Almura Hospital	50	23 (46.0)	
King Saud Medical City	58	36 (62.1)	
Riyadh Care Hospital	30	13 (43.3)	
<b>Profession</b>			0.822
Cardiologist	18	14 (77.8)	
Endocrinologist	12	4 (66.7)	
Family Medicine	26	14 (53.8)	
Internist	74	30 (40.5)	
Nephrologist	8	6 (75.0)	
<b>Degree obtained</b>			0.050
Saudi Saudi Arabia	32	15 (46.9)	
Outside Saudi Arabia	105	56 (53.3)	
<b>Years of practice</b>			<0.001
<5	27	9 (33.3)	
5-15	53	33 (62.3)	
>15	58	30 (51.7)	

\* Assessment used t-test Mann-Whitney U test or the Chi-square test

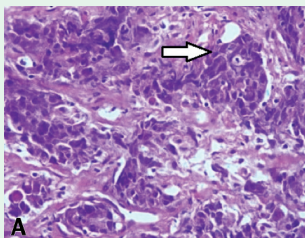
Practices of the Use of ACE Inhibitors and ARBs (N=138)

Sukkarieh et al conclude that there is a universal agreement among physicians regarding the use of angiotensin-converting enzyme (ACE) and angiotensin II receptor blockers (ARBs) for the treatment of diabetic nephropathy (DN) with limited awareness of the benefits of using vitamin D. Hence, the development of specific guidelines for its use are recommended. The vast majority recommended clearer guidelines on monitoring renal function in patients treated with ACEi or ARBs. Forty-one physicians reported the use of combination therapy of ACEi and ARBs. Fifty-six physicians reported that they never used vitamin D in the treatment of DN, and 48% agreed that vitamin D can benefit patients with DN. The authors used the IBM SPSS 26.0 to perform descriptive statistical analyses and comparisons were based on the Chi-square test.

see page 1083

## CASE REPORT

### Nasopharyngeal carcinoma metastasis to the breast



Microphotography showing poorly differentiated malignant cells (hematoxylin-eosin at magnification x 40)

Albarisi present a case of a 43-year-old Mauritanian female patient presented with a mass in her left breast and swelling in her left axillary region. A histopathological examination of the mass showed enlarged polygonal tumor cells with scant to moderate, eosinophilic to amphophilic cytoplasm and enlarged, hyperchromatic and pleomorphic nuclei with irregular nuclear membranes. An immunohistochemistry (IHC) examination was positive for pan cytokeratin and negative for CK7, CK20, S-100, LCA, HMB45, CD 20, desmin, myogenin, GCFDP-15, transcription factor-1, villin, estrogen receptor, progesterone receptor, and human epidermal growth factor receptor 2. The patient was deceased 3 months after refusing the recommended medical intervention.

see page 1130