

REVIEW ARTICLE

A contemporary look at thyroid nodule management. *What every Saudi physician and surgeon should know*

Merdad discuss the substantial changes to the methods of thyroid nodule management in the past decade, including new guidelines for performing thyroid ultrasound and biopsy. In Saudi Arabia, the incidence of thyroid nodule detection and the subsequent diagnosis of incidental thyroid cancers is expected to rise. Genetic tests are now routinely used in some centers to aid in the diagnosis of thyroid nodules. Guidelines are available to aid in the categorization and risk stratification of thyroid nodules based on ultrasonographic and cytopathological features. High-volume thyroid surgeons have lower risk of surgical complications compared to low-volume surgeons. Papillary thyroid cancer has an excellent prognosis, particularly in young patients and in early stages of the disease. Some papillary thyroid cancers are now reclassified as non-invasive follicular thyroid neoplasm with papillary-like nuclear features, a premalignant neoplasm and not a cancer, with an extremely low likelihood of recurrence.

see page 123

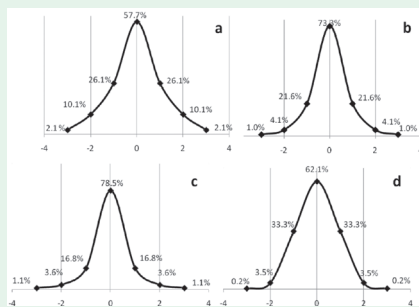
ORIGINAL ARTICLES

Variables associated with subclinical atherosclerosis among rheumatoid arthritis patients of Gulf Cooperative Council countries

Hannawi et al, evaluate the cardiovascular disease (CVD) as demonstrated by carotid intima-media thickness (cIMT) and the cluster risk factors of CVD including traditional and non-traditional, urinary functions, iron buildup, and hemorheology in 216 rheumatoid arthritis (RA) patients of Gulf Cooperative Council (GCC) countries. The mean cIMT was observed as 0.58 ± 0.11 mm. Mean age was 48 ± 13 years. Univariate analysis revealed a positive association ($p < 0.05$) between cIMT and age, body mass index, systolic blood pressure (SBp), and diastolic blood pressure, c-reactive protein (CRP), triglycerides (TG), low-density lipoprotein (LDL), erythrocyte sedimentation rate (ESR), hemoglobin (Hb), hematocrit (Hct), mean cell volume, platelet, monocytes, eosinophils, ferritin, creatinine, and uric acid. Negative relationship was observed between cIMT and glomerular filtration rate (GFR), transferrin, and high-density lipoprotein. In this study, it was found that the eosinophils, and low transferrin, are the potential candidates for the CVD risk factors in RA patients. Fasting blood glucose level was also observed to be a significant risk factor in diabetic as well as non-diabetic RA. The remaining CVD risk factors in RA patients of GCC countries including older age, high SBp, ESR, LDL, and low GFR were similar to the international population.

see page 128

Corneal elevation indices and pachymetry values of Saudi myopes using scheinplflug imaging



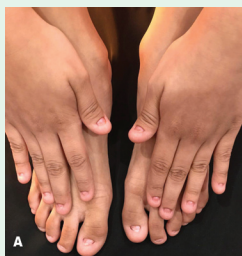Standard normal distribution curve for posterior elevation at A) 5mm, B) 8mm, C) apex, and D) the thinnest posterior elevation.

Alsaif et al, conclude the corneal elevation indices and thicknesses specific to the Saudi myopes were found to be comparable to the international databases in terms of the elevation and thickness in some of the parameters. The sample was comprised of 1,276 patients; 838 (65.7%) had simple myopia and 438 (34.3%) had myopic astigmatism. All of the measurements, except the apical PE and thinnest PE, were statistically significant across the simple and myopic astigmatism groups ($p < 0.05$).

see page 168

CASE REPORT

Anonychia congenita in different generations of a single Saudi family



Total anonychia of all nails of fingers and toes of patient

Bin Nooh et al present 3 cases with anonychia congenita appearing in different generations of a single family in Kingdom of Saudi Arabia. Anonychia refers to the absence of nail plates owing to an autosomal dominant or recessive inheritance. Congenital anonychia is a rare condition that may be associated with other ectodermal or mesodermal malformations like epidermolysis bullosa, (deafness, onychodystrophy, osteodystrophy, and mental retardation) syndrome and Iso-Kikuchi syndrome. Genetic analysis will be employed to confirm the diagnosis.

see page 195