

# Pediatric foreign body ingestion in Makkah, Saudi Arabia

## A retrospective epidemiological study

Bayan O. Besharah, MD, SBORL, Rehab F. Simsim, MD, SBORL, Lina Y. Natto, MD, Ahmad J. Khiyami, MD, Abed A. Aqeel, MD, SBORL.

### ABSTRACT

**الأهداف:** تحسين بياناتنا المحلية حول مدى انتشار الحالات المشخصة بابتلاع جسم غريب لدى الأطفال في منطقة مكة المكرمة بالمملكة العربية السعودية، وإضافة دراسة إحصائية أساسية جديدة تُقدم الفائدة للدراسات المستقبلية في مجتمعنا المحلي.

**المنهجية:** أجرينا دراسة وصفية وبأثر رجعي شملت 153 طفل من الذين قدموا إلى مركزنا وشخصوا كحالة ابتلاع جسم غريب خلال الفترة الزمنية من ديسمبر 2014 إلى ديسمبر 2019. تم استبعاد البالغين والحالات التي تم فيها ابتلاع مواد كيميائية أو وجود الأجسام الغريبة خارج الجهاز الهضمي.

**النتائج:** في هذه الدراسة تم إجراء تحليل إحصائي وصفي وأوضح الدراسة تزايد في عدد الحالات المشخصة كحالة ابتلاع جسم غريب والتي احتاجت إلى التنويم في المستشفى. ما يقارب (41.8%) من الحالات كانت لأطفال أقل من 4 سنوات، والنسبة الأكبر منها (63.4%) كانت من الذكور. تم ابتلاع عملة معدنية في غالبية الحالات بنسبة (60.8%)، ونسبة (96.7%) من الحالات تم تنويمهم تحت الملاحظة في المستشفى لأقل من 24 ساعة. تُظهر النتائج علاقة ذات دلالة إحصائية عالية بين أنواع الأجسام الغريبة فيما يتعلق بالعمر والإقامة في المستشفى ونتائج المنظار المريئي.

**الخلاصة:** تناول الأجسام الغريبة أكثر شيوعاً بين الأطفال وخاصة فيمن هم دون عمر الرابعة وقد تتراوح أعراض الفحص السريري من المضاعفات غير المصحوبة بأعراض إلى المضاعفات الشديدة، والتدخل العاجل بالمنظار الذي قد يكون قتل من خطورة المضاعفات. من الضروري اتخاذ المزيد من التدابير الوقائية داخل المنزل، كما أن هناك حاجة إلى المزيد من التثقيف الصحي لمقدمي الرعاية حول الظروف المختلفة لابتلاع الأجسام الغريبة، والوقت اللازم للذهاب العاجل إلى المستشفى والحاجة إلى التدخل الجراحي.

**Objectives:** To improve the local data and demographics of foreign body (FB) ingestion in the Makkah, Saudi Arabia and to provide basic statistics for future studies in the local community.

**Methods:** We carried out a record-based retrospective epidemiological study of 153 pediatric patients with FB ingestion who presented to our center in Makkah, Saudi Arabia, between December 2014 and December 2019. Adult age, impacted FB at other sites, and chemical ingestion were excluded.

**Results:** Descriptive statistical analyses were performed. There has been an alarming increase in the number of children admitted to hospitals

following FB ingestion. Approximately 41.8% of these patients were under the age of 4 years, with boys (63.4%) accounting for the majority. Most of the ingested FB were coins (60.8%), and 96.7% of the patients remained under 24 hours of observation at the hospital. The results showed a highly statistically significant relationship between the FB type, age, length of hospital stay, and esophagosopic findings.

**Conclusion:** A large number of children presented with ingested FB, especially those younger than 4 years of age, whose clinical presentation varied from asymptomatic to severe complications, and urgent endoscopic intervention might have decreased serious complications. Further preventive measures are necessary within homes in addition to increasing caregivers' awareness of the different circumstances of FB ingestion and the time required for urgent admission.

**Keywords:** endoscopy, esophagoscopy, foreign body, ingestion, pediatrics

*Saudi Med J* 2023; Vol. 44 (6): 594-600  
doi: 10.15537/smj.2023.44.6.20230090

From the Department of Otolaryngology-Head and Neck Surgery (Besharah), King Abdullah Medical Complex; from the Department of Urology (Khiyami), International Medical Center, Jeddah; from the Clinical Science Department (Simsim), College of Medicine, Princess Nourah Bint Abdulrahman University, Riyadh; from the Department of Otolaryngology-Head and Neck Surgery (Natto), King Abdullah Medical City; from the Department of Otolaryngology-Head and Neck Surgery (Aqeel), Al-Noor Specialist Hospital, Makkah, Kingdom of Saudi Arabia.

Received 5th February 2023. Accepted 11th May 2023.

Address correspondence and reprint request to: Dr. Bayan O. Besharah, Department of Otolaryngology-Head and Neck Surgery, King Abdullah Medical Complex, Jeddah, Kingdom of Saudi Arabia.  
E-mail: Bayan.o.b@gmail.com  
ORCID ID: <https://orcid.org/0000-0001-5514-3680>

Foreign body (FB) ingestion is the accidental or intentional swallowing of an object that can affect the esophagus.<sup>1</sup> The presentation differs depending on the location, size, and nature of the FB. Coughing, difficulty in breathing, nausea, vomiting, chest pain, and fever are possible symptoms.<sup>2</sup>

Foreign body impaction in the esophagus is a common and serious health problem worldwide, with 2.5 million cases reported each year in the United States; in most cases the patients are younger than 5 years old.<sup>2</sup> Esophageal FB is commonly observed in children, as their lack of molars and curiosity may lead to the placement of the FBs in the mouth.<sup>1,2</sup> According to Abualenain et al,<sup>1</sup> most FB ingestion occurs in children aged 0–4 years. Moreover, variations in incidence have been observed between male and female patients.<sup>1</sup>

The diagnosis of FB ingestion can be challenging for clinicians, especially when the event is not witnessed or when the child is asymptomatic.<sup>3</sup> Children who complain of sore throat or have trouble swallowing saliva or meals for no obvious reasons should be suspected of having esophageal FBs. If an esophageal FB does not pass naturally within 24 hour (h), it must be removed to prevent esophageal anatomical injury (such as erythema, edema, ulceration, or perforation) that can lead to serious complications.<sup>2,4,5</sup>

In one literature review, the reported FBs included coins, batteries, safety pins, food boluses, buttons, magnets, and toys of which coins were the most common FBs ingested by children.<sup>1,2</sup> Abualenain et al<sup>1</sup> found that approximately 74% of swallowed FBs were coins, and 49% of all FB types were managed with upper endoscopy. Coins in the esophagus must be removed as quickly as possible because they can lead to serious complications if left untreated. Early detection of foreign materials is crucial to avoid catastrophic issues, such as atelectasis, pneumonia, bronchiectasis, suffocation, and mortality.<sup>2</sup>

Our literature search did not find any studies of the prevalence of FB ingestion among children in the Makkah region. In this study, we explored the prevalence of FB ingestion in pediatric patients at the Otolaryngology Head and Neck (ORL-H&N) department of Al-Noor Specialist Hospital (NSH), the only hospital in Makkah that receives and manages such cases, as well as to enhance the local data for different

types of FB ingestion, management, and outcomes and to increase awareness of the hazards of FB ingestion with an exhortation to keep such items out of reach of children. This can be implemented through educational programs on social media, in nurseries, and in schools.

**Methods.** This was a record-based retrospective review of a prospectively maintained demographic and clinical database of 153 patients with FB ingestion, including all pediatric patients who presented to the emergency department with FB ingestion and were admitted to the ORL-H&N department at NSH, Makkah, between December 2014 and December 2019.

Inclusion criteria of the study included all pediatric patients (neonates to 14 years old) admitted because of an FB impact on the esophagus who underwent chest radiography (CXR). While the exclusion criteria were patients older than 14 years with FB ingestion or impacted FB at other sites (such as the ear, trachea, nose, and bronchial tree) and chemical ingestion were excluded.

This study was approved by the Institutional Review Board of the Ministry of Health in Makkah (registration number: H-02-K-076-0320-282).

Two authors collected data by reviewing the electronic records of the Al-Noor Specialist Hospital database system, including admissions data such as patient demographic characteristics (age, gender, and nationality) and clinical presentation (duration of hospital stay, symptoms, previous history of FB ingestion, and CXR findings). Details of the hospital course, including the need for rigid upper endoscopy, intra-operative upper endoscopy findings, and FB type, were also recorded.

**Statistical analysis.** The data were analyzed using the Statistical Package for Social Sciences, version 26 (IBM Corp., Armonk, NY, USA). Participant variables were estimated using descriptive statistics, including frequency counts and percentages of categorical variables. To detect relationships between different categorical qualitative variables, a Chi-square ( $\chi^2$ ) test was used. Results were considered statistically significant when the significance ( $p$ -value) was  $<0.05$ . A  $p$ -value  $<0.001$  was considered highly statistically significant (HS), and a  $p$ -value of 0.05 was considered statistically non-significant (NS).

**Results.** This study included 155 patients admitted to NSH with FB ingestion. Two patients without FB were also identified. Therefore, a final total of 153 patients were included in this study.

**Disclosure.** Authors have no conflict of interests, and the work was not supported or funded by any drug company.

Of the patients presenting with FB, 41.8% were between the ages of 1 and 4 years, and 38.6% were between the ages of 5 and 8 years. Most patients with FB (71.2%) were Saudi Arabian, and more than half (63.4%) were male. The results are presented in **Table 1** and **Figure 1**.

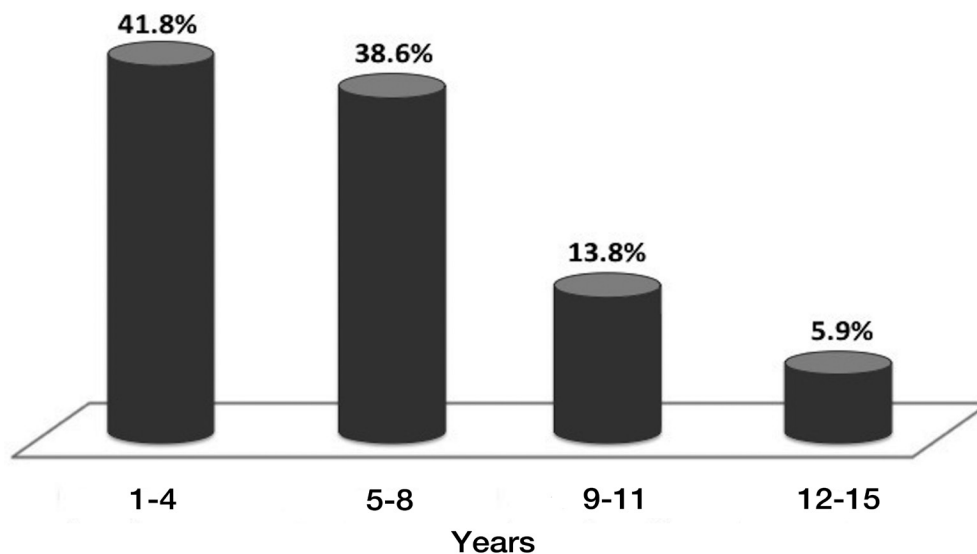
Approximately 94.8% of the patients had no symptoms. None of the patients had a history of FB ingestion. Most patients (96.7%) remained under 24-h observation at the hospital (**Table 2**).

Regarding the CXR findings, 96.1% of the FB appeared in the CXR from C1 to T4. Most patients (95.4%) required a rigid upper endoscopy. More than half of the patients (60.1%) experienced no complications. Most cases involved metallic FB (60.8%) in the form of coins (**Table 2 & Figure 2**).

Our results showed a highly statistically significant ( $p<0.001$ ) relationship between the types of FB and age, as the highest incidence of coin ingestion (44.1%) was observed in the age group of 5-9 years, whereas 81% of the cases of battery ingestion were in patients aged 1-4 years. There was a highly significant ( $p<0.001$ ) relationship between the type of FB and hospital stay, with 1% of coin FB and 19% of battery FB ingestion cases needing to stay in the hospital for >24 h. There was a statistically significant ( $p<0.001$ ) relationship between the types of FB and the need for rigid upper endoscopy. Regarding esophagoscopy findings, 71.4% of the cases showed that the ingestion of batteries was associated with complications such as esophageal injury. The other parameters and different foreign body-type relationships are listed in **Table 3**.

**Table 1** - Patients' basic characteristics in the studied group.

Variables	Study group (N=153)	
	n	(%)
<i>Age (years)</i>		
1-4	64	41.8
5-8	59	38.6
9-11	21	13.8
12-15	9	5.9
<i>Nationality</i>		
Saudi	109	71.2
Non Saudi	44	28.8
<i>Gender</i>		
Male	97	63.4
Female	56	36.6

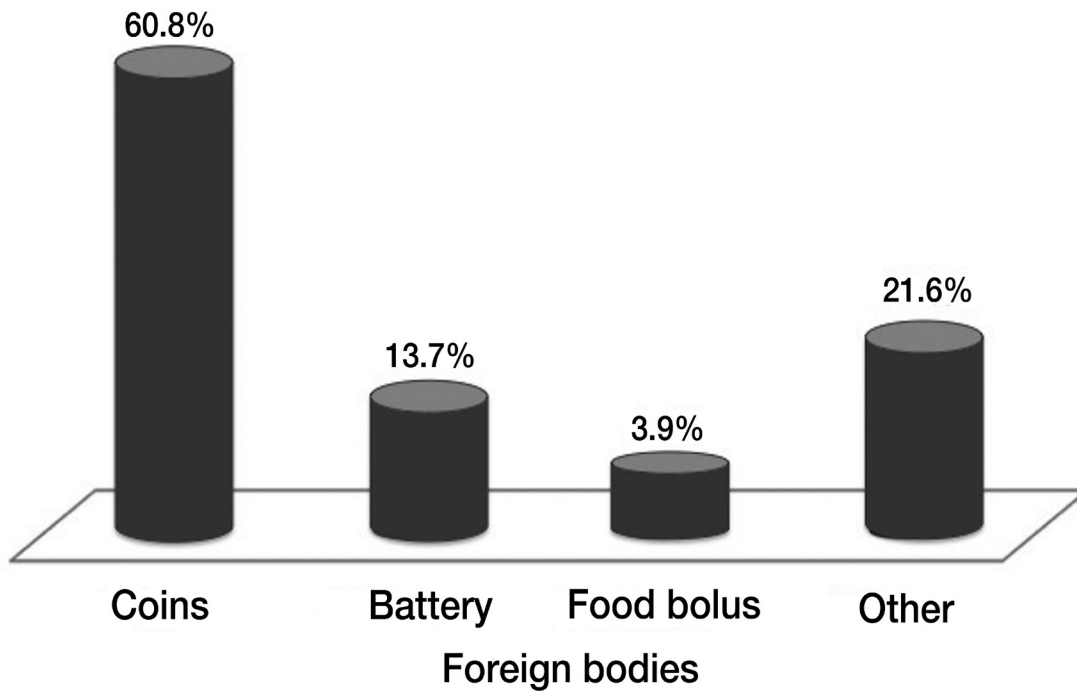


**Figure 1** - Age distribution of the patients in the studied group.

**Table 2** - Clinical presentations of the studied group.

Variables	Study group (N=153)	
	n	(%)
<i>Symptoms</i>		
No symptom	145	94.8
Odenophagia	8	5.0
<i>Previous history of FB ingestion</i>		
Yes	0	0
No	153	100
<i>Hospital stay</i>		
24 hours	148	96.7
More than 24 hours	5	3.3
<i>Chest x-ray finding</i>		
No FB seen	6	3.9
(C1–C6)	82	53.6
(C7–T4)	65	42.5
<i>Need for rigid upper endoscopy</i>		
Yes	145	95.4
No	7	4.6
<i>Esophageoscopy finding</i>		
No operation	39	25.5
Complication	22	14.4
No complication	92	60.1
<i>Type of foreign body</i>		
Coin	93	60.8
Battery	21	13.7
Food bolus	6	3.9
Other	33	21.6

FB: foreign body



**Figure 2** - Types of foreign bodies ingested in the studied group.

**Table 3 -** Relationship between types of foreign body and different parameters.

Variables	Type of foreign body								P-value	Pair analysis	
	Coin n=93		Battery n=21		Food bolus n=6		Other n= 3				
	n	%	n	%	n	%	n	%			
<b>Clinical presentation</b>	<i>Age</i>										
	(1-4)	29		17	81	1	16.7	17	51.5	<0.001	P1 = 0.001
	(5-8)	41		4	19	1	16.7	13	39.4	<0.406	P2 = 0.001
	(9-11)	19		0	0	1	16.7	1	3	<0.847	P3 = 0.103
	(12-15)	4	4.3	0	0	3	50	2	6.1	<0.355	P4 = 0.001
	<i>Previous history of FB ingestion</i>										
	No	93	100	21	100	6	100	33	100	0.531	P5 = 0.147
											P6 = 0.009
	<i>Hospital stay</i>										
	24 hours	92		17	81	6	100	33	100		P1 = 0.649
	> 24 hours	1	1.1	4	19	0	0	0	0	<0.001	P2 = 0.177
											P3 = 0.516
											P4 = 0.247
											P5 = 0.936
											P6 = 0.256
<b>Hospital course</b>	<i>Chest x-ray finding</i>										
	No FB seen	0	0	0	0	4	66.7	2	6.1	<0.001	P1 ≤ 0.001
	(C1-C6)	53	57	8	38.1	2	33.3	19	57.6	<0.733	P2 = 0.798
	(C7-T4)	40	43	13	61.9	0	0	12	36.4	<0.453	P3 = 0.550
											P4 = 0.247
											P5 = 0.009
	<i>Need for rigid upper endoscopy</i>										
	Yes	90		20	100	3	50	32	97		P1 = 0.117
	No	3	3.2	0	0	3	50	1	3	<0.001	P2 ≤ 0.001
											P3 = 0.956
											P4 = 0.001
											P5 = 0.432
											P6 ≤ 0.001
	<i>Esophageoscopy finding</i>										
	No operation	27	29	4	19	2	33.3	6	18.2	<0.001	P1 ≤ 0.001
	Complication	1	1.1	15	71.4	2	33.3	4	12.1	<0.351	P2 ≤ 0.001
	No complication	65		2	9.5	2	33.3	23	69.7	<0.817	P3 = 0.014
											P4 = 0.193
											P5 ≤ 0.001
											P6 = 0.212

P1: Coin versus (vs.) Battery group, P2: Coin vs. Food group, P3: Coin vs. Others group, P4: Battery vs. Food group, P5: Battery vs. Others group, P6: Food vs. Others group

**Discussion.** Foreign body ingestion is considered a common health concern and mostly occurs in children between the ages of 6 months and 3 years. However, the majority (80%-90%) of FBs pass through the gastrointestinal tract (GIT) without complications, and only 10%-20% require upper rigid endoscopic removal. Age, body weight, clinical findings, shape, type, and time of FB ingestion are essential parameters for the timing of endoscopic removal.<sup>6</sup> In this study, we analyzed the data collected from the ORL-H&N

departments of patients who had ingested FB. Most of the 153 children were aged 1-4 (41.8%) years. This is consistent with the findings of Navia-López et al,<sup>7</sup> who carried out a cross-sectional study of the prevalence of FB ingestion between 2013 and 2018 in 85 patients with a median age of 4 years. Foreign body ingestion was high in this age group, owing to their exploratory habits. Another study by Al Lawati et al<sup>8</sup> showed that 50.9% of patients with FB were below 3 years of age. A slight male predominance (63.4%) was seen in the



gender distribution, similar to the finding that 58.4% of children diagnosed with FB ingestion in Oman between 2011 and 2014 were boys.<sup>8</sup>

Of the various FBs ingested by the children, coins were the most common in this study (60.8%). The same finding was reported by a study carried out at King Abdulaziz University, Jeddah, Saudi Arabia which included 117 pediatric patients who ingested FBs between 2011 and 2020. Coins were the most frequent FBs (48.2%), and most FBs (63.6%) affected the upper esophagus.<sup>9</sup> Similarly, a study from the Jazan region showed that 68.5% of FBs ingested were coins. They also found that the incidence of removal of coin FB ingestion markedly increased after coin currency implementation from 16.1% of all cases to 83.9%.<sup>10</sup> Moreover, Orsagh-Yentis et al<sup>11</sup> reported a significant increase in the incidence of FB ingestion to 91.5% per 10000 children in the United States between 1995 and 2015.

Button batteries are frequently used in electronic devices; therefore, the incidence of their accidental ingestion has increased.<sup>5</sup> Because button batteries are of the same size and shape as coins and the 2 types of FB are frequently difficult to distinguish, x-ray screening is required to prevent delays in diagnosis.<sup>12</sup> However, it is difficult to identify the magnetitic FB single or multiple only by radiological methods such as x-ray and computed tomography (CT) scans.<sup>4</sup> Moreover, battery size is a deciding factor in complications. Lee et al<sup>12</sup> reported that children who ingested batteries <15 mm in size were asymptomatic and passed them without complications, whereas those who ingested >15 mm batteries showed moderate to severe complications.

Gatto et al<sup>13</sup> reported a significant relationship between the morphology of ingested FBs and presence of symptoms. Approximately 47% of cases with sharp FBs were symptomatic, whereas coins were associated with symptoms in only 20%. However, morphology was not significantly associated with the length of hospital stay or endoscopic removal. In a study by Speidel et al,<sup>14</sup> 38.1% of patients who ingested batteries needed a 24-hour hospital stay. Similarly, the current study observed a statistically significant relationship between the types of FB and length of the hospital stay.

Recent guidelines recommend performing 2-projection radiography (lateral and anteroposterior) in all patients who ingest FBs, including asymptomatic cases.<sup>13,15</sup> However, some sharp objects are radiolucent, which reduces the positive predictive value of radiographic findings.<sup>13</sup> In the current study, 2-projection radiography was performed in all patients. Most FB were visualized at the C1–C6 (53.6%) and

C7–T4 (42.5%) sites. Coins are commonly located at C1–C6, thereby confirming a highly statistically significant relationship between FB type and CXR characteristic findings, as the sensitivity to detecting coins in x-rays was 100%, which is consistent with the findings of other studies.<sup>9,16</sup> In other studies, the FB was not visualized by x-ray in 43% of cases, and this was related to the different characteristics of the FB.<sup>13</sup>

The need for intervention depends on the characteristics of the ingested FB, time of impaction to decrease complications, and location. According to the North American Society for Pediatric Gastroenterology, Hepatology, and Nutrition (NASPGHAN) guidelines for endoscopic intervention in FB cases, ingested batteries should be removed within 2 h even if the patient is asymptomatic. The same time frame applies to the other types of FBs in children with excessive and unmanageable oral secretions. Asymptomatic children may be observed for up to 24 h. However, esophageal impaction of long FBs should be removed within 24 h, regardless of the presence or absence of symptoms.<sup>5</sup>

In this study, examination findings of rigid upper endoscopy showed a highly statistically significant relationship between complications and the type of FB. Intra-operative esophagoscopy findings reported that 71.4% of battery ingestion cases were associated with different grades of esophageal injury (such as erythema, edema, abrasion, and ulceration) as complications, whereas a low incidence of complications was observed with the ingestion of coins. This may be due to differences in the type, size, and location of FB; variable time until hospital admission (as many parents try to manage at home first and others require time to reach the hospital); median time between consultation and extraction; clinical presentation; and presence of other morbidities, as discussed in the literature.<sup>7,9</sup> Others have reported esophageal perforation as a complication from sharp FB ingestion in one patient (among 76) who underwent upper endoscopy.<sup>7</sup> Practical and rapid management strategies are advised to reduce the possibility of complications.<sup>4</sup>

**Study limitations.** The current study contributes retrospective epidemiological data on the characteristics of pediatric patients admitted with FB ingestion and provides information regarding the location and type of FB. In addition, diagnostic and therapeutic endoscopy plays an important role in the emergency management of FB ingestion. However, as our results depended on retrospective data, one of the limitations of this study is that some key statistics could not be obtained, significant biases might have affected the selection of participants, and the researchers could not control for exposure or outcome assessment. Another limitation is

that as the sample was convenience-selected, the results cannot be generalized.

In conclusion, this study showed that FB ingestion is a common problem in children, especially in those under 4 years of age and male. Most cases were asymptomatic, and clinical presentations varied depending on the type of FB, patient age, and duration of hospital referral. Urgent endoscopy performed within 24 h of exposure can reduce the incidence of complications and unnecessary stress, highlighting the importance of prompt medical attention. Caregivers should be educated on the different circumstances of FB ingestion and the urgency of seeking medical attention. By doing so, patient outcomes can be improved and resource utilization can be optimized.

**Acknowledgment.** *The authors express their deep appreciation to their supervisor and adviser Dr. Tariq Alaydaros. We would also like to thank Editage (www.editage.com) for the English language editing.*

## References

1. Abualenain TJ, Jawa HA, Baintaleb YY, Abulkalam MM, Aldini MA, Dafterdar AK, et al. Emergency Department experience of foreign body ingestion: An analysis of 69 cases in an academic hospital in Saudi Arabia. *Eurasian J Emerg Med* 2018; 17: 3-8.
2. AlShakhs F, AlYahya K, AlSaeed A, AlSultan M. Parental awareness regarding aerodigestive pediatric foreign bodies: Eastern province, Saudi Arabia. *Egypt J Hosp Med* 2018; 70: 1511-1517.
3. Altokhais TI, Al-Saleem A, Gado A, Al-Qahtani A, Al-Bassam A. Esophageal foreign bodies in children: Emphasis on complicated cases. *Asian J Surg* 2017; 40: 362-366.
4. Altokhais T. Magnet ingestion in children management guidelines and prevention. *Front Pediatr* 2021; 9: 727988.
5. Fadl AA, Alhazmi AAM, Alyami TM, Alkhaldi NJ, Alhamdan AS, Alsaedi WM, et al. Overview on gastrointestinal foreign bodies in children. *J Pharm Res Int* 2021; 33: 49-58.
6. Diaconescu S, Gimiga N, Sarbu I, Stefanescu G, Olaru C, Ioniuc I, et al. Foreign bodies ingestion in children: Experience of 61 cases in a pediatric gastroenterology unit from Romania. *Gastroenterol Res Pract* 2016; 1982567.
7. Navia-López LA, Cadena-León JF, Ignorosa-Arellano KR, Toro-Monjaraz EM, Zárate-Mondragón F, Loredó-Mayer A, et al. Foreign body ingestion and associated factors in pediatric patients at a tertiary care center. *Rev Gastroenterol Mex (English Edition)* 2021; 87: 20-28.
8. Al Lawati TT, Al Marhoobi R. Patterns and complications of ingested foreign bodies in Omani children. *Oman Med J* 2018; 33: 463.
9. AlKhatib T, Zawawi F, BinTaleb Y, Bustanji N, AlMahmoudi A, AlZaidi T, et al. Approach to pediatric esophageal foreign body ingestion: An experience of 117 cases in a tertiary care center. *Saudi J Otorhinolaryngol Head Neck Surg* 2022; 24: 99-105.
10. Wafi A, Wafi M, Hakami T, Alabida NW, Almutairi R, Alsaleh S, et al. Incidence of pediatric rigid esophagoscopy for foreign body removal before and after coin currency implementation in Saudi Arabia in 2017. *Ann Saudi Med* 2022; 42: 415-418.
11. Orsagh-Yentis D, McAdams RJ, Roberts KJ, McKenzie LB. Foreign-body ingestions of young children treated in US emergency departments: 1995–2015. *Pediatrics* 2019; 143: e20181988.
12. Lee JH. Foreign body ingestion in children. *Clin Endosc* 2018; 51: 129.
13. Gatto A, Capossela L, Ferretti S, Orlandi M, Pansini V, Curatola A, et al. Foreign body ingestion in children: Epidemiological, clinical features and outcome in a third level emergency department. *Children* 2021; 8: 1182.
14. Speidel AJ, Wölflle L, Mayer B, Posovszky C. Increase in foreign body and harmful substance ingestion and associated complications in children: A retrospective study of 1199 cases from 2005 to 2017. *BMC Pediatrics* 2020; 20: 560.
15. Kodituwakku R, Palmer S, Paul SP. Management of foreign body ingestions in children: Button batteries and magnets. *Br J Nurs* 2017; 26: 456-461
16. Sink JR, Kitsko DJ, Mehta DK, Georg MW, Simons JP. Diagnosis of pediatric foreign body ingestion: Clinical presentation, physical examination, and radiologic findings. *Ann Otol Rhinol Laryngol* 2016; 125: 342-350.