

Traumatic retropharyngeal hematoma

A systematic review of reported cases

Abdullah A. Alabdulqader, MD, Norah A. Almudawi, Medical Student, Shabad M. Alkhonezan, Medical Student, Mohammed A. Almudawi, Medical Student, Manal M. Alkhonezan, Medical Student, Ghada A. Alshebri, MD, Abdullah M. Alnatheer, MD.

ABSTRACT

الأهداف: دراسة آليات الإصابة، والمظاهر السريرية، والنتائج الإشعاعية، والإدارة، والنتائج المتعلقة بالأورام الدموية خلف البلعوم الناجمة عن الإصابات.

المنهجية: تم استخدام PRISMA لإجراء مراجعة بحثية للدراسات لتحديد جميع الحالات المنشورة للأورام الدموية خلف البلعوم الناتجة عن الإصابات من خلال البحث في قاعدة بيانات PubMed. تم تضمين المقالات التي نشرت بين عامي 1988 و 2022 والتي تناولت الأورام الدموية خلف البلعوم الناتجة عن الإصابات. في حين استبعدت هذه الدراسة المقالات التي تناولت الأورام الدموية خلف البلعوم الناتجة عن الاضطرابات العفوية أو غير الناتجة عن الإصابات والمقالات غير الإنجليزية.

النتائج: من بين 62 مقالة تم فحصها، تم تضمين 56 مقالة. وقد كان معظم المرضى (55%) في سن متجاوزة عمر الـ 61.7 عامًا. وكان معظم المرضى من الذكور (69.7% مقابل 30.3%). وكان أكثر الأعراض السريرية شيوعاً هو ضيق التنفس (66.6%) وعادة ما تظهر الأعراض خلال 24 ساعة. ومن بين المرضى، لم يكن لدى 90.9% منهم تاريخ استخدام مضادات التخثر أو اضطرابات تخثر الدم، وكانت السقوط (54.5%) هو السبب الرئيسي للإصابة. وكانت معظم النتائج التي تم الإبلاغ عنها بواسطة الحاسوب المقطعي للجسم تشير إلى أورام دموية خلف البلعوم (38%) وقيل الفقرية (15%). وفي الوقت نفسه، كشف التصوير بالرنين المغناطيسي عن كتلتين في مساحة خلف البلعوم وعن ورمين دمويين خلف البلعوم. وباستخدام عدة أساليب علاجية، تم مراقبة أكثر من 50% من الحالات (44 حالة، 63.8%)، وكان تنبيب القصبة الهوائية هو أكثر طريقة استخداماً لإدارة مجرى الهواء (35 حالة).

الخلاصة: كان السقوط هو السبب الأكثر شيوعاً لحدوث أورام دموية خلف البلعوم الناجمة عن الإصابات، في حين كان المرضى في معظم الحالات من كبار السن. وكان ضيق التنفس هو الأعراض الأكثر شيوعاً، وكان معظم المرضى يبدأون في الشعور بالأعراض خلال الـ 24 ساعة الأولى. وتعد كسور الفقرات الرقبية هي السبب الأكثر شيوعاً لحدوث أورام دموية خلف البلعوم الناجمة عن الإصابات، وكانت الملاحظة هي التقنية العلاجية الأكثر استخداماً.

Objectives: To study the mechanisms of injury, clinical manifestations, radiological findings, management, and outcomes of traumatic retropharyngeal hematoma (RH).

Methods: We used the Preferred Reporting Items of Systematic Reviews guidelines to carry out a systematic literature review to identify all published cases of traumatic RH by searching the PubMed database. Articles published between 1988 and 2022 that reported traumatic RH were included. However, articles that reported non-traumatic RHs and non-English articles were excluded from this study.

Results: Of the 62 articles screened, 56 were included. Most patients (55%) were above the mean age of 61.7. The majority of patients were male (69.7%). The main symptom was dyspnea (66.6%) and symptoms usually presented within 24 hours. Among the patients, 90.9% did not take anticoagulants or have coagulation disorders, and the main injury mechanism was falling (54.5%). Most of the computed tomography findings reported retropharyngeal (38%) and prevertebral (15%) hematoma. Meanwhile, magnetic resonance imaging revealed 2 masses in the retropharyngeal space and 2 RHs. With several treatment modalities, more than 50% of the cases were only observed (44 cases), and endotracheal intubation was the most commonly used airway management method (n=35).

Conclusion: Traumatic RH is often caused by falls, particularly in elderly patients. Dyspnea is the primary symptom, usually appearing within 24 hours. Cervical vertebral fractures are the leading cause, and observation is the most common treatment approach.

PROSPERO Reg. No.: CRD42022349010

Keywords: retropharyngeal hematoma, traumatic retropharyngeal hematoma, systematic review, cervical trauma

Saudi Med J 2024; Vol. 45 (1): 10-26
doi: 10.15537/smj.2024.45.1.20230565

From the Department of Otorhinolaryngology-Head and Neck Surgery (Alabdulqader), College of Medicine, Imam Mohammad Ibn Saud Islamic University; from the Collage of Medicine (N. A. Almudawi, S. M. Alkhonezan, M. A. Almudawi, M. M. Alkhonezan, Alshebri), Imam Mohammad Ibn Saud Islamic University, and from the Department of Emergency Medicine (Alnatheer), King Faisal Specialist Hospital & Research Centre, Riyadh, Kingdom of Saudi Arabia.

Received 31st July 2023. Accepted 6th November 2023.

Address correspondence and reprint request to: Dr. Norah A. Almudawi, Collage of Medicine, Imam Mohammad Ibn Saud Islamic University, Riyadh, Kingdom of Saudi Arabia. E-mail: Norahalmudawi@gmail.com
ORCID ID: <https://orcid.org/0009-0008-2168-1454>

Retropharyngeal hematoma (RH) is a potentially fatal condition where the airway is entirely blocked by the expanding hematoma.¹⁻⁸ It may be noticed in a variety of ways based on their size and rate of emergence.⁹⁻¹³ The deep and medium layers of the cervical fascia are separated by the retropharyngeal space, which extends from the base of the skull to the superior mediastinum at the level of the second thoracic vertebra. Blood entering this area is what causes RH.¹¹ It can be brought on by a number of conditions, including infection, severe vascular damage, cervical spine fracture, forceful head movements, metastasis, parathyroid adenoma hemorrhage, iatrogenic injury, and ingestion of a foreign material.¹⁴⁻²³

Spontaneous RH is an uncommon type of RH that arises without a known cause.^{8,19,21,24,25} Particularly, anticoagulation therapy or hemorrhagic diathesis may predispose individuals to RH.^{26,27} Retropharyngeal hematoma is frequently found in trauma patients, particularly those with cervical injuries. According to Penning et al,²⁸ the prevertebral gap is wider in 60% of individuals with cervical injury. However, RH only causes airway obstruction in 1.2% of patients.²⁹ Predominantly, traumatic RH occurs after a cervical vertebral fracture and is generally higher than C6.³⁰⁻³⁴ According to one research, the most common RH-related injuries included skull fractures, rib fractures, long bone fractures, mandibular fractures, thoracic aortic dissection, lung contusion, brachial plexus damage, and cranial nerve VI palsy.³⁵

Initial symptoms include pharyngitis, dyspnea, odynophagia, and dysphagia (which can occur alone or in various combinations) while bruising, pain, and increasing neck swelling can occasionally clarify the diagnosis. Cervical trauma frequently happens in patients for a number of causes, from severe car accidents to minor falls.⁹⁻¹³ However, RH is typically difficult to diagnose owing to its scarcity and lack of distinct indications and diagnostic laboratory evidence in the majority of patients.^{19,20,24} Patients with RH have a fair prognosis for recovery, with only a few reported cases of fatal outcomes.^{5,36,37} The first step in clinical care is securing a patient's airway, followed by clinical examination and radiographic investigations to obtain a diagnosis. Treatment is determined by the size and clinical course of the hematoma.³⁸ This study

aimed to investigate the mechanism of injury, clinical presentation, radiological findings, management, and outcomes of traumatic RH.

Methods. This study was designed in accordance with the Preferred Reporting Items of Systematic Reviews (PRISMA) criteria for recommended reporting items for systematic reviews and meta-analyses. We searched the PubMed database, supplemented by manual reference searches for all published research articles, using the following keywords: [(“traumatic retropharyngeal hematoma”) AND (“case report”)] and [(“retropharyngeal hematoma”) AND (“case report”)] and (“fall”) and [(“retropharyngeal hematoma”) AND (“case report”)] AND (“accident”) and [(“traumatic retropharyngeal hematoma”) AND (“motor vehicle collision”)] to decrease the possibility of missed cases. The search was carried out by 7 investigators. We included all studies published between 1988 and 2022. We excluded: I) non-English studies; II) systematic reviews, review articles, and randomized control trials; and III) spontaneous and non-traumatic RH. The following data was independently gathered by 4 authors from the included studies: author, publishing year, age, gender, anticoagulation/coagulopathy, mechanism of injury, presenting symptoms, time from injury to symptoms (hours), associated injuries, associated findings in computed tomography (CT) scan, associated findings on magnetic resonance imaging (MRI) scan, techniques for controlling airways, treatment modality, acute complication, The reason of death, and intensive care unit (ICU).

Results. A total of 62 articles were identified using PubMed (**Figure 1**), and the manual reference search yielded 21 additional articles. After excluding 3 duplicate papers, 80 were reviewed by title and abstract. A total of 9 records with apparently non-traumatic or irrelevant subjects and 3 records with no abstract were removed. We evaluated the remaining 68 articles according to the eligibility criteria. The following factors led to the exclusion of another 12 articles: insufficient information (n=8) and in languages other than English (n=4). Finally, a total of 56 articles were included (**Figure 1**).

Patients ranged in age from 4-94 years (median: 68 years). Most patients (56.5%) were above the mean age of 61.7. Furthermore, in line with the patterns observed in most trauma reports, there was a clear male predominance among patients diagnosed with traumatic RH, with males accounting for 69.7% of the

Disclosure. Authors have no conflict of interests, and the work was not supported or funded by any drug company.

cases compared to females, who accounted for 30.3%. Most patients (90.9%) were not taking anticoagulants or diagnosed with coagulation disorders, but 9.1% were taking warfarin or heparin. The main injury mechanism was falls (54.5%), followed by traffic accidents (34.8%). Common symptoms of RH were dyspnea (66.6%), dysphagia (31.8%), neck swelling (31.8%) and pain (30.3%), stridor (25.7%), hoarseness (22.7%), altered

mental status (18.2%), and cyanosis (12.1%, **Figure 2**). Where time to symptoms was recorded, symptoms presented within the first 24 hours (**Table 1**).

A total of 52 articles reported radiological CT findings and found the following number of cases: hypoattenuating retropharyngeal collection (n=1, 2%), prevertebral soft tissue swelling (n=10, 15%), prevertebral hematoma (n=10, 15%), cervical fractures

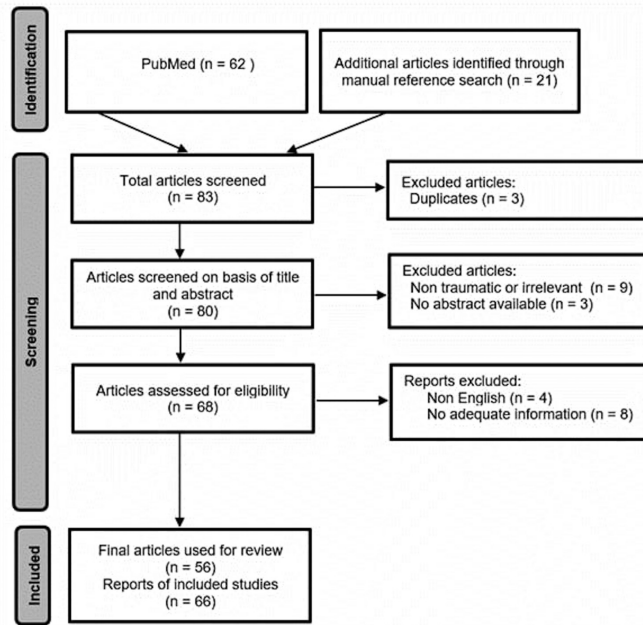


Figure 1 - The Preferred Reporting Items of Systematic Reviews guidelines flow diagram.

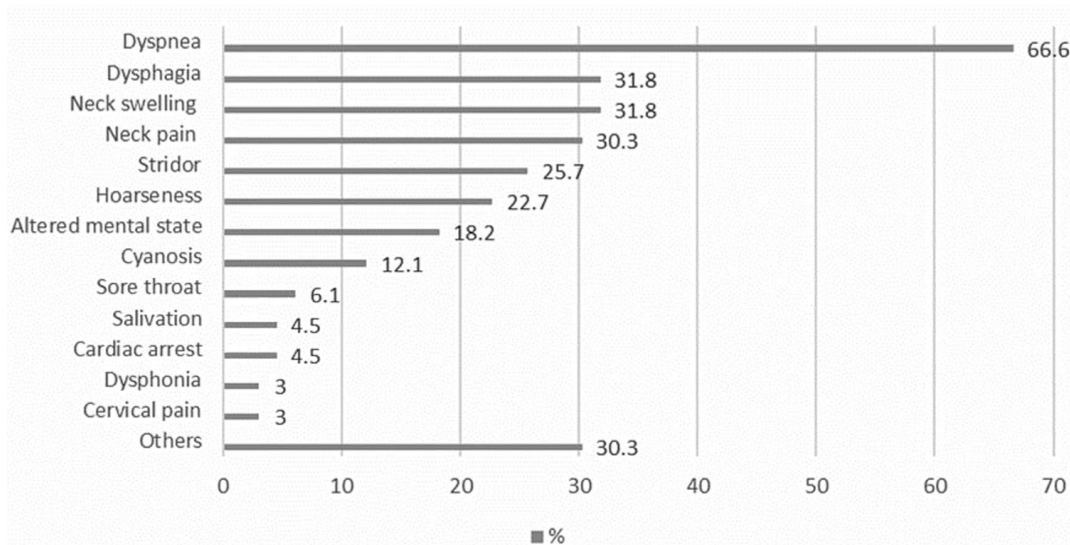


Figure 2 - Common symptoms for patients with traumatic retropharyngeal hematoma.

Table 1 - Characteristics of the included patients in reviewed articles.

Case no.	Authors	Year of publication	Ages	Genders	Anti-coagulation/coagulopathy	Mechanism of injury	Presenting symptoms	Time from injury to symptoms (hours)	Associated injuries
1.	Smith et al ³⁹	1988	77	F	No Hx	Fall	Neck pain, dysphagia, stridor, dyspnea, forehead ecchymosis	Unknown	0
2.	Myssiorek et al ¹⁰	1989	80	M	No Hx	MVA	Dysphagia, hoarseness, dyspnea	2 hrs.	0
3.	Biby et al ⁴⁰	1990	27	F	No Hx	MVA	AMS, neck pain, trismus, dysphagia	Unknown	Odontoid fracture, cranial nerve VI palsy
4.	Kuhn et al ²⁹	1991	22	M	No Hx	Motorcycle accident	Stridor, dyspnea, salivation	Unknown	Mandibular fracture, C5, 6 fracture subluxation
5.	Kuhn et al ²⁹	1991	70	M	No Hx	MVA	AMS, cyanosis, dyspnea	Unknown	Mandibular fracture, C2, 3 fracture subluxation, C7 fracture
6.		1991	58	M	No Hx	Fall	Stridor, salivation	Unknown	C1-3 fractures
7.		1991	82	M	No Hx	Fall	Dyspnea, stridor	Unknown	Clavicle fracture
8.		1991	22	M	No Hx	MVA	Dyspnea	Unknown	C6 quadriplegia
9.	Kuhn et al ²⁹	1991	75	M	No Hx	MVA	Dyspnea	½ hrs.	C4, 5 fractures
10.		1991	92	M	No Hx	Fall	Dyspnea	1 hrs.	T4 quadriplegia
11.		1991	83	M	No Hx	MVA	Cardiac arrest	11 hrs.	C4,5 fractures and dislocation, quadriplegia
12.	Daniello et al ⁴¹	1994	57	F	No Hx	Fall	Dyspnea, dysphagia, epistaxis	Unknown	0
13.	Shaw et al ⁴²	1995	Unknown (elderly)	M	No Hx	Pedestrian struck by a car	Dysphagia, odynophagia, dyspnea, hoarseness, neck swelling	Unknown	0
14.	Mitchell et al ¹¹	1995	28	F	No Hx	MVA	AMS, hoarseness, stridor, neck pain, agitation	Unknown	0
15.	O'Donnell et al ⁴³	1997	19	M	No Hx	Motorcycle accident	Neck swelling, cyanosis, AMS, hematemesis, apnea, pulseless	Unknown	Atlantooccipital fracture and dislocation
16.	Mazzon et al ⁴⁴	1998	81	M	No Hx	MVA	Obtunded, cyanosis, symptoms of upper airway obstruction, neck swelling, AMS	Unknown	C4, 5 fractures
17.	Cox et al ⁴⁵	1998	13	F	No Hx	Bicycle accident	AMS, neck swelling, neck pain, stridor	Unknown	Skull fracture
18.	Senthuran et al ¹³	1999	68	F	No Hx	Fall	Fever, dyspnea, cyanosis, bradycardia	Unknown	0
19.	Sandooram et al ⁹	2000	78	M	Warfarin	Fall	Dyspnea, dysphonia, dysphagia, tachypneic, stridor, salivation	Unknown	0
20.	Vakees et al ⁴⁶	2000	88	F	No Hx	Fall	dyspnea, hoarseness, neck swelling	6 hrs.	0
21.	Kette et al ⁴⁷	2000	67	M	No Hx	Fall	AMS, neck pain, dyspnea, hoarseness	Unknown	0
22.	El Kettaniet al ⁴⁸	2002	37	M	No Hx	MVA	Dyspnea, dysphagia, neck pain, stridor	10 hrs.	Clavicle fracture, C6 fracture

M: male, F: female, Hx: history, C: cervical spine, MVA: motor vehicle accidents, AMS: altered mental status

Table 1 - Characteristics of the included patients in reviewed articles. Continuation

Case no.	Authors	Year of publication	Ages	Genders	Anti-coagulation/coagulopathy	Mechanism of injury	Presenting symptoms	Time from injury to symptoms (hours)	Associated injuries
23.	Van Velde et al ⁴⁹	2002	84	F	No Hx	Fall	Dyspnea, stridor, sore throat, neck swelling	5 hrs.	0
24.	Shiratori et al ⁵⁰	2003	40	M	No Hx	Skiing accident	neck pain, dyspnea	Immediately	Tracheal displacement
25.	Kochilas et al ⁵¹	2004	53	M	No Hx	Fall	stridor, dysphonia, neck swelling, dysphagia	4 hrs.	0
26.	Suzuki et al ⁵³	2004	67	M	No Hx	MVA	dyspnea, neck pain, cervical pain, cyanosis, AMS	Immediately	C5 fracture
27.	Anagnostara et al ⁵²	2005	58	M	No Hx	MVA	Dyspnea, dysphagia, sore throat, hoarseness, cyanosis	Unknown	0
28.	Chiti-Batelli et al ⁵³	2005	54	F	Warfarin	Fall	Dysphagia, hoarseness, dyspnea	20-21 hrs.	0
29.	Duvillard et al ⁵⁴	2005	40	M	No Hx of anti	Struck by metallic lump	Dyspnea, dysphagia	Unknown	0
30.		2005	94	M	No Hx of anti	Fall	Dysphagia	Unknown	0
31.	Freeman et al ⁵⁵	2005	31	M	No Hx	Motorcycle accident	Cervical pain	Unknown	0
32.	Lin et al ³²	2006	50	M	No Hx	Fall	Dyspnea, hoarseness, neck swelling	Unknown	0
33.	Sheah et al ⁵⁶	2006	90	M	No Hx	Fall	Stridor, neck swelling	Unknown	Tracheal dislocation and compression
34.	Wyngaert et al ⁵⁷	2006	27	M	No Hx	MVA	Neck pain, dyspnea, stridor	Unknown	Occipital condyles fracture, anterior arcus of the atlas fracture
35.	Takeuchi et al ⁵⁸	2007	31	M	No Hx	Motorcycle accident	Neck pain, dyspnea, hoarseness	Unknown	Atlantooccipital dislocation, cervical subdural hematoma, traumatic subarachnoid hemorrhage, mandibular fracture.
36.	Lazott et al ⁵⁹	2007	50	M	No Hx	Fall	Neck pain, dyspnea, hoarseness	Unknown	Brachial plexus injury, C1 fracture
37.	Srivastava et al ⁶⁰	2008	85	F	Warfarin	Fall	Stridor	Unknown	0
38.	Tsai et al ³⁰	2008	40	M	No Hx	Fall	Dyspnea, dysphonia, throat pain, neck pain	Unknown	0
39.	Birkholz et al ⁶¹	2010	77	M	No Hx	MVA	Dyspnea and hypoxic cardiac arrest.	Unknown	Leg fracture, C2 fracture, partial tetraparesis, larynx dislocation
40.	Morita et al ⁶²	2010	92	M	No Hx	Fall	Sore throat, dyspnea and neck pain	6 hrs.	Ligament injury, minor vascular injury around the injured ligament

M: male, F: female, Hx: history, C: cervical spine, MVA: motor vehicle accidents, AMS: altered mental status

Table 1 - Characteristics of the included patients in reviewed articles. Continuation

Case no.	Authors	Year of publication	Ages	Genders	Anti-coagulation/coagulopathy	Mechanism of injury	Presenting symptoms	Time from injury to symptoms (hours)	Associated injuries
41.	Wronka et al ⁶³	2011	89	M	No Hx	Fall	Dysphagia, dysarthria, dyspnea, stridor, hoarseness	168 hrs.	C2 fracture and displacement
42.	Pfeiffer et al ⁶⁴	2011	92	F	No Hx	Fall	Dyspnea, dysphagia, odynophagia	10 hrs.	All cervical spine injury
43.	Lin et al ⁶⁵	2011	84	F	Warfarin	Fall	Capp's triad, dyspnea, neck swelling	Unknown	Tracheal dislocation and compression
44.	Ottaviani et al ⁶⁶	2011	77	F	Heparin	Iatrogenic	Hoarseness, sore throat, dysphagia	48 hrs.	0
45.	Senel et al ³⁸	2012	86	F	No Hx	Fall	Dyspnea, cyanosis, neck swelling	Unknown	0
46.	Jakanani et al ⁶⁷	2012	65	F	No Hx	Fall	Dyspnea, cardiac arrest	Unknown	C5 fracture, prevertebral hematoma
47.	Nurata et al ⁶⁸	2012	4	M	No Hx	Somersault	Neck stiffness, neck pain	Unknown	0
48.	Iizuka et al ⁶⁹	2012	30	F	No Hx	MVA	Dyspnea, neck swelling, AMS	Unknown	C4-7 fracture, Intracranial hemorrhage
49.	Paul et al ⁷⁰	2015	75	M	No Hx	Fall	Neck pain, dysphagia, dyspnea, AMS, stridor, hoarseness, and cyanosis.	Unknown	0
50.	Thamamongood et al ⁷¹	2015	77	F	No Hx	Fall	Neck swelling, odynophagia	Unknown	0
51.	Park et al ⁷²	2015	51	M	No Hx	Fall	Neck pain, dyspnea.	Unknown	0
52.		2015	78	M	No Hx	Fall	Neck swelling, dyspnea	4 hrs.	0
53.	Calogero et al ⁷³	2015	80	M	No Hx	Fall	Dysphagia, hoarseness, neck swelling,	Unknown	0
54.	Kudo et al ⁷⁴	2017	83	F	No Hx	MVA	AMS, dyspnea, hemorrhagic shock, neck swelling	Unknown	Subarachnoid hemorrhage, C4, 5 dislocations
55.	Lowe et al ⁷⁵	2017	60	F	No Hx	Fall	hoarseness, dysphagia, neck pain, neck swelling	Unknown	Upper aerodigestive tract distortion, loss of normal cervical lordosis
56.	Betten et al ⁷⁶	2018	81	F	No Hx	Fall	Stridor, Dyspnea, AMS	10 hrs.	0
57.	Ren et al ⁷⁷	2019	55	M	No Hx	Iatrogenic	Cervical swelling, dysphagia	33 hrs.	0
58.	Devarakonda et al ⁷⁸	2019	22	M	No Hx of anti	Fall	-----	Unknown	Fracture angle (left) Parasymphysis (right) of mandible +trauma in the oropharynx.
59.	Chang et al ⁷⁹	2019	93	M	No Hx	Fall	Neck swelling	Unknown	Incomplete quadriplegia
60.		2019	53	M	No Hx	MVA	Neck pain	Unknown	0

M: male, F: female, Hx: history, C: cervical spine, MVA: motor vehicle accidents, AMS: altered mental status

Table 1 - Characteristics of the included patients in reviewed articles. Continuation

Case no.	Authors	Year of publication	Ages	Genders	Anti-coagulation/coagulopathy	Mechanism of injury	Presenting symptoms	Time from injury to symptoms (hours)	Associated injuries
61.	Arai et al ⁸⁰	2020	75	M	No Hx	Fall	Dyspnea, AMS	Unknown	Cervical cord injury
62.	Yu et al ⁸¹	2020	55	M	No Hx	Bicycle accident	Dyspnea, neck swelling	Unknown	0
63.	Iida et al ⁸²	2020	79	M	Warfarin	Fall	Neck pain, back pain, dyspnea	4 hrs.	Cervical spine at the C3 level, as well as a fracture in the spinous process of the cervical spine.
64.	Baek et al ⁸³	2020	49	M	No Hx	MVA	Dyspnea, neck swelling	Unknown	0
65.	Kitai et al ⁸⁴	2021	75	M	No Hx	Fall	Dysphagia, neck swelling	6 hrs.	Left scapula fracture, left fifth metacarpal fracture
66.	Patel et al ⁸⁵	2021	83	M	No Hx	Blunt force trauma by the closing doors	Neck pain, dysphagia, stridor	1-1.5 hrs.	0

M: male, F: female; Hx: history; C= cervical spine; MVA: motor vehicle accidents; AMS: altered mental status.

(n=9, 13%), occipital condylar fractures (n=2, 3%), retropharyngeal soft tissue swelling (n=4, 6%), RH (n=26, 38%), a pharyngeal mass (n=5, 7%), and cervical spondylosis (n=1, 2%, [Table 2](#)).

Out of 12 articles that used MRI, one showed a low-signal retropharyngeal collection on T1, 2 showed a low-signal mass in the retropharyngeal space, and one showed a slightly high-signal at C4 and C5. On T2, one showed a high-signal retropharyngeal collection and one showed a heterogeneous mass along the retropharyngeal space, 2 RHs, one retropharyngeal swelling, and one tearing of the anterior longitudinal ligament at C4-5 level ([Table 2](#)).

Several treatment modalities were reported: the majority of cases were only under observation (n=44, 63.8%), followed by surgery (n=13, 18.8%), percutaneous aspiration (n=7, 10.1%), and transcatheter arterial embolization (n=5, 7.2%). Of the 69 cases, only 16 (23%) cases were admitted to the ICU. There were 8 (11.6%) cases of mortality due to multiple system organ failure (n=5, 7.2%), hemodynamic instability (n=1, 1.4%), or withdrawal of life support (n=2, 2.9%, [Figure 3](#)).

Only 12 (17.4%) patients suffered from acute complications including pneumonia, pulmonary edema, type 2 respiratory failure, mucosal and submucosal edema of the pharyngeal wall, months of difficulty swallowing, anoxic brain damage, venous thrombus, and stroke.

The most common first option airway management procedure was endotracheal intubation (n=35, 50.7%), which failed in 16 (23.2%) cases ([Table 3](#)).

Tracheostomy was also a first-option procedure (n=7, 10%) but more often used as a second option (n=12, 17.4%) when endotracheal intubation was unfeasible. Cricothyroidotomy was used in only 4 (5.8%) cases, and 8 (11.6%) underwent none of the aforementioned airway management procedures ([Figure 4](#)).

Discussion. Retropharyngeal hematomas are life-threatening conditions due to the possibility of progressive obstruction of the upper airways. A spontaneous unprovoked bleeding is highly unusual, and the condition is often associated with underlying conditions such as cervical spinal cord injury, trauma with or without bone damage, and neck surgery. The primary strategy is to protect the airway and to provide intensive care.

In many cases, patients with spinal cord injuries and fractures are suffering from RH, and their clinical course and outcome are determined by the primary injury they have sustained. As a result, the natural clinical course of RH remains unclear.⁸⁸

Demographics and causes. Traumatic RHs are most commonly caused by cervical vertebral fractures, and are generally higher than C6.^{12,29,89,41,42} According to one study Tsao et al,³⁵ the most common injuries were cervical spinal injuries, traumatic brain injuries, long bone fractures, mandibular fractures, lung contusion,

Table 2 - Radiological findings of reported cases of RPH.

Authors	Modality	Findings
Smith et al ²⁷	CT	Large homogeneous mass gradually occluding the airway at the level of hypopharynx.
Biby et al ²⁹	CT	A severe prevertebral soft tissue swelling.
Kuhn et al ³¹	CT	I) 4 weeks later, soft tissue swelling occluding airway.
		II) Cervical spine revealed a C5 and C6 pedicle fracture with subluxation and mild widening of the prevertebral soft tissue. Three days later, retropharyngeal soft-tissue swelling and prominent degenerative osteophytes anteriorly that contribute to airway obstruction.
		III) Breakage from C1's transverse process to C2's lamina, a dens fracture, and a fracture of the transverse process of C3, with moderate prevertebral soft-tissue swelling.
		IV) Not stated.
		V) Not stated.
		VI) Complete fracture dislocation of C4 on C5 and extensive prevertebral soft-tissue swelling.
		VII) Significant degenerative alterations in the cervical spine and a 4-mm posterior displacement of C5 on C6.
		VIII) Widespread soft-tissue edema before vertebrae.
Daniello et al ³³	CT	There is a large mass located in the retropharyngeal area that extends from the base of the skull to the top of the lungs.
Shaw et al ³⁴	CT	The imaging showed a fluid-filled cavity in the retropharyngeal space that extended from the second to the sixth cervical vertebrae. The cavity was also found to be enhancing.
Mitchell et al ³⁵	CT	Retropharyngeal hematoma with the trachea outlined only by the endotracheal tube.
Mazzon et al ³⁷	CT	The imaging revealed a large hematoma that extended from the second cervical vertebra to the upper mediastinum. The hematoma occupied the entire pharyngeal and parapharyngeal space, and it caused compression of the upper larynx.
Cox et al ³⁸	CT	The imaging showed that there was an occipital skull fracture that was not displaced, significant swelling of the soft tissue in front of the vertebrae, and compression of the airway from outside.
Senthuran et al ³⁹	CT	The imaging revealed a significant mass in the retropharyngeal region on the left side, measuring 4 × 5 cm. The mass extended from the level of the hyoid bone to the left atrium, and it caused an indentation and anterior displacement of the trachea. Additionally, it blocks the left lower lobe bronchus.
Vakees et al ⁴¹	CT	The imaging showed a significant swelling of the soft tissue behind the trachea, which was consistent with a large hematoma that extended from the retropharyngeal and tracheal regions into the posterior mediastinum and base of the skull.
Kette et al ⁴²	CT/MRI	CT: neck edema and hemorrhagic infarction of the peripharyngeal and perilaryngeal tissue, deformed upper airway, perivertebral muscular structures were no more recognizable, and vascular nervous fascia included within the mass without compressed, a discrete amount of air was documented at the level of perithyroidal.
		MRI: cervical spine contusion at c3-c4 and c5-c6 levels in pre-existing vertebral spondylotic stenosis, the vertebral channel was stenotic, hemorrhagic infarction attributed to hematoma was documented at the same level prevertebral space.
Kettani et al ⁴³	CT	According to the imaging, there was a hematoma that stretched from the fourth cervical vertebra to the upper mediastinum and filled the pharyngeal space, and the sixth cervical vertebra had a fracture.
Velde et al ⁴⁴	CT	From the base of the skull to the superior mediastinum and the carina, there is a hematoma in the retropharyngeal area. Goiter is indicated by calcifications and nodules on the thyroid gland.
Shiratori et al ⁴⁵	CT	The trachea is severely narrowed due to a large hematoma that extends from the pharynx to the point where the trachea splits into 2 branches. The narrowing is most severe at the level of the sternoclavicular joint, and the trachea has been pushed forward from its normal position.
Kochilas et al ⁴⁶	CT	After 12 hours with intravenous contrast, it was suggested that the swelling was caused by a hematoma rather than soft tissue edema.
Suzuki et al ⁴⁷	CT	The CT scan of the neck with 5 mm slices revealed that the retropharyngeal space is widened, and there is an obstruction in the upper airway.
Anagnostara et al ⁴⁸	CT/MRI	CT: revealed a retropharyngeal collection that was hypoattenuating and located in the midline, anterior to the swollen prevertebral musculature. It extended from C1-C6 level. Additionally, there was an anterior displacement and compression of the parapharyngeal space, as well as lateral displacement of the carotid space, which were demonstrated bilaterally. The arytenoid cartilages were likewise somewhat shifted anteriorly, more caudally
		MRI: following the absorption of the prevertebral edema, axial T1 and T2 weighted MRI scans at the level of the tongue base show that the airway has been cleansed. Retropharyngeal collection, which is T2 hyperintense and T1 hypointense, is barely discernible.
Chiti-Batelli et al ⁴⁹	CT	A mass was identified in the mediastinum that is consistent with a hematoma extending to the carina.
Duvillard et al ⁵⁰	CT	I) A retropharyngeal hematoma that is massive and extends from the second to the seventh cervical vertebra is present.
		II) A retropharyngeal hematoma is present between C3 and C7, which is causing a mass effect on the larynx, trachea, and pharynx without any vertebral fracture.
Freeman et al ⁵¹	CT	Imaging of the head was unremarkable. However, type I bilateral occipital condylar fractures with little displacement were found from C0-C2.
Lin et al ⁵²	CT	Demonstrate the presence of a retropharyngeal hematoma that is obstructing the airway and causing breathing difficulties.
Sheah et al ⁵³	CT	A massive low-density retropharyngeal hematoma that stretched from the base of the skull to the mediastinum was visible on the CT image. The suspicion was of extravagance.

RPH: retropharyngeal hematoma, CT: computed tomography, MRI: magnetic resonance imaging

Table 2 - Radiological findings of reported cases of RPH. Continuation

Authors	Modality	Findings
Wyngaert et al ⁵⁴	CT/MRI	The CT scan showed a fracture of the anterior arcus of the atlas and a bilateral fracture of the occipital condyles. Both bone fragments were displaced inferomedially towards the medulla. A type III OCF, according to the classification of Anderson and Montesano, was also detected. MRI: the cervical epidural hematoma with obliteration of the anterior perimedullary space (curtain-sign) was discovered on the MRI, which also verified the OCFs. On the other hand, medullary pathology was not evident.
Lazott et al ⁵⁶	CT/MRI	The CT scan showed bilateral fractures of the anterior arch of C1 and a fracture of the right C4 spinous process. Mild prominence of prevertebral soft tissues was noted without significant encroachment on the pharynx. MRI: an expanding hematoma was the cause of the noticeable increase in the prevertebral soft tissue prominence seen on the sagittal T2-weighted MRI with fat saturation techniques.
Srivastava et al ⁵⁷	CT	The CT scan revealed a fracture of the right C4 spinous process in addition to bilateral fractures of the C1 anterior arch. There was a slight prevertebral soft tissue prominence without a noticeable pharyngeal encroachment.
Tsai et al ⁵⁸	CT	There was a massive hematoma visible on the CT scan that stretched from the base of the skull to the thoracic inlet. Both of the carotid arteries had extravasated contrast material inside of them as well as lateral displacement.
Birkholz et al ⁵⁹	CT	Fracture of C2, extended retropharyngeal and mediastinal hematoma. The pharynx, the larynx, and the trachea were obstructed by the hematoma, suggestive for partial bilateral basal ganglia infarction.
Morita et al ⁶⁰	CT/MRI	CT: a large hematoma that stretched from the superior mediastinal space to the retropharyngeal was visible on the CT scan. MRI: at the C4-5 levels, a sagittal MRI (T2-weighted) showed anterior longitudinal ligament tearing.
Wronka et al ⁶¹	CT	The CT scan showed a type 2 fracture through the junction of the odontoid peg and body of C2. The body of C2 was displaced anteriorly by approximately 11 mm. There was an associated surrounding hematoma and soft tissue edema.
Pfeiffer et al ⁶²	CT	confirmed that a large retropharyngeal haematoma narrowed the pharyngeal lumen.
Lin et al ⁶³	CT	A large retropharyngeal hematoma that extended between the C2 and T4 vertebral body levels was visible on the CT scan. The trachea was compressed and moved as a result of the hematoma.
Ottaviani et al ⁶⁴	CT	The CT scan showed a retropharyngeal hematoma measuring 7 cm by 3 cm on the right side. The hematoma caused a mass effect on the pharynx and larynx. Additionally, severe cervical spondylosis was present.
Senel et al ⁶⁵	CT	A hypodense 3 x 1.5 cm region at the level of C2 and the left anterior border of the trachea was visible on the CT scan. There was a cannula inside the trachea, which was twisted to the right.
Jakanani et al ⁶⁶	CT	The CT scan revealed a small retrolisthesis of C5 on C6, as well as a reduction in the C5/C6 disc interspace. A C5 lamina fracture that was consistent with a hyperextension injury was also discovered by CT scanning. CT: the prevertebral spaces were wider, and the CT scan revealed an X-mm soft tissue mass compressing the trachea between C1 and C4.
Nurata et al ⁶⁷	CT/MRI	MRI: on T2-weighted sagittal and axial MRI images, diffuse edema completely obscured the left retropharyngeal space. A retropharyngeal hematoma is consistent with the significant pharyngeal airway narrowing that resulted from this.
Iizuka et al ⁶⁸	CT/MRI	The CT scan showed a brain contusion in the right frontal lobe, C4-7 right transverse process fracture, no visualization of the right vertebral artery, and extravasation of the contrast agent around the right transverse process fracture. The MRI revealed a massive retropharyngeal hematoma located anteriorly, extending from the C1-T3 vertebrae. This was responsible for the sudden asphyxia. The same MRI also detected avulsion of the right lower cervical roots.
Paul et al ⁶⁹	CT	Evidence of large retropharyngeal hematoma, measuring approximately 11 cm by 2.4 cm by 4 cm in size and causing severe compression of the adjacent airway
Thamamongood et al ⁷⁰	CT	A soft tissue mass in the posterior mediastinum, retropharyngeal space, and bilateral carotid space was visible on the CT scan. It appeared isodense to hypodense. The mass compressed the upper esophagus posteriorly and extended caudally to the level of the eighth thoracic vertebra. D) The CT scan showed no definite fracture or vessel injury. However, in the second CT, it revealed a prevertebral hematoma and a dark air density region at the C6-7 disc. There was no fracture or vascular injury on CT angiography.
Park et al ⁷¹	CT/MRI	MRI: the same patient's T2-weighted sagittal MRI revealed a longitudinal mass in the retropharyngeal space from the C3 to T2 levels with heterogeneous signal intensity. The signal intensity was high for the C4 and C5 bodies. The same patient's T1-weighted sagittal MRI revealed a low signal intensity mass in the retropharyngeal space. While the signal intensity at the upper C4 body was low, it was slightly higher at the lower C4 and C5 bodies. II) Not possible due to poor compliance.
Calogero et al ⁷²	CT	A sizable hematoma, measuring 6.7 cm transversely and 3.2 cm anteroposteriorly, is located in the retropharyngeal space. The hematoma is believed to have originated from the thyrocervical trunk and is situated posterior to the thyroid gland level. It measures 25 centimeters in length and begins at the level of the lower nasopharynx. It continues down the neck into the retropharyngeal space and into the mediastinum posterior to the esophagus. The hematoma causes esophageal compression in addition to anterior deviation of the larynx. Prevertebral soft tissue swelling is seen in the cervical spine, which causes the endotracheal tube to move anteriorly. Unintentionally, the abdomen revealed a 4.8 cm abdominal aortic aneurysm.
Kudo et al ⁷³	CT/MRI	A retropharyngeal hematoma and C4/C5 dislocation were visible on the CT scan. Bilateral occipital watershed infarctions were seen on the MRI; they did not seem to be causing any symptoms.

RPH: retropharyngeal hematoma, CT: computed tomography, MRI: magnetic resonance imaging, OCF: occipital condylar fracture

Table 2 - Radiological findings of reported cases of RPH. Continuation

Authors	Modality	Findings
Lowe et al ⁷⁴	CT	Retropharyngeal hematoma
Betten et al ⁷⁵	CT	The CT scan was normal, but a large retropharyngeal hematoma measuring 3.6 cm by 5.3 cm by 20 cm was detected.
Ren et al ⁷⁶	MRI	A significant C4/5 and C5/6 disc herniation with severe spinal cord compression is visible on the sagittal cervical spine MRI. On T2-weighted images, there is an abnormally hyperintense signal in the spinal cord at the C5/6 level. A massive retropharyngeal hematoma that extends from the base of the skull to T1 is visible on the sagittal T2-weighted MRI 35 hours after surgery. This hematoma severely compresses the laryngopharynx and oropharynx posteriorly. A massive incisional hematoma between the trachea and carotid sheath is visible on the axial T2-weighted MRI.
Chang et al ⁷⁸	CT/MRI	CT: I) a type II dens fracture (Anderson-D'Alonzo classification) and the Wackenheim line running behind the dens, indicating posterior AOD, were both visible on the CT scan. II) The CT scan additionally revealed a posterior AOD-indicating type II dens fracture with comminution (Anderson-D'Alonzo classification) and a running of the Wackenheim line behind the dens. A combined horizontal and sagittal split fracture of the C1 anterior arch and a type II dens fracture with comminution were identified on the coronal and axial reconstructed CT scans. Furthermore, a type II TAL injury was suggested by an avulsion fragment from the lateral mass of C1 and a widened right atlantodental interval seen on an axial CT scan. MRI: increased anterior soft tissue swelling as a result of intramedullary hemorrhage and retropharyngeal hematoma was seen on the MRI. The axial MRI showed a type II TAL injury in accordance with Dickman's classification and a midline sagittal split fracture of the C1 anterior arch.
Arai et al ⁷⁹	CT	Massive retropharyngeal hematoma
Yu et al ⁸⁰	CT	In the retropharyngeal space, a sizable hematoma that stretched from the base of the skull to the posterior mediastinum was discovered. Additionally, there was evidence of contrast leakage at the C6-7 vertebral level.
Iida et al ⁸¹	CT	There is a sizable hematoma measuring 53 × 145 × 25 mm in the retropharyngeal space. The patient also has a cervical spine spinous process fracture and a cervical fracture (C3). At the C7 vertebral body level, contrast agent extravasation was observed in the hematoma, which is compressing the hypopharynx and larynx.
Baek et al ⁸²	CT/MRI	CT: no definite fracture or vessel injury was detected. However, an intense retropharyngeal hematoma was found. MRI: a heterogeneous signal intensity mass in the retropharyngeal space is visible on the T2-weighted sagittal MRI. A mass with low signal intensity is visible in the retropharyngeal space on the T1-weighted sagittal MRI.
Kitai et al ⁸³	CT	There was no evidence of a retropharyngeal space anomaly or spinal fracture. Nonetheless, fractures on the left fifth metacarpal and scapula were discovered.
Patel et al ⁸⁴	CT	The nasopharynx and supraglottic larynx are effaced anteriorly due to opacification of the entire retropharyngeal (danger) tissue space (mean 65 HU), which stretches from the base of the skull to the mediastinum. This is caused by a noticeable mass effect.

RPH: retropharyngeal hematoma, CT: computed tomography, MRI: magnetic resonance imaging, AOD: atlantooccipital dislocation, TAL: transverse atlantal ligament, HU: hounsfield units

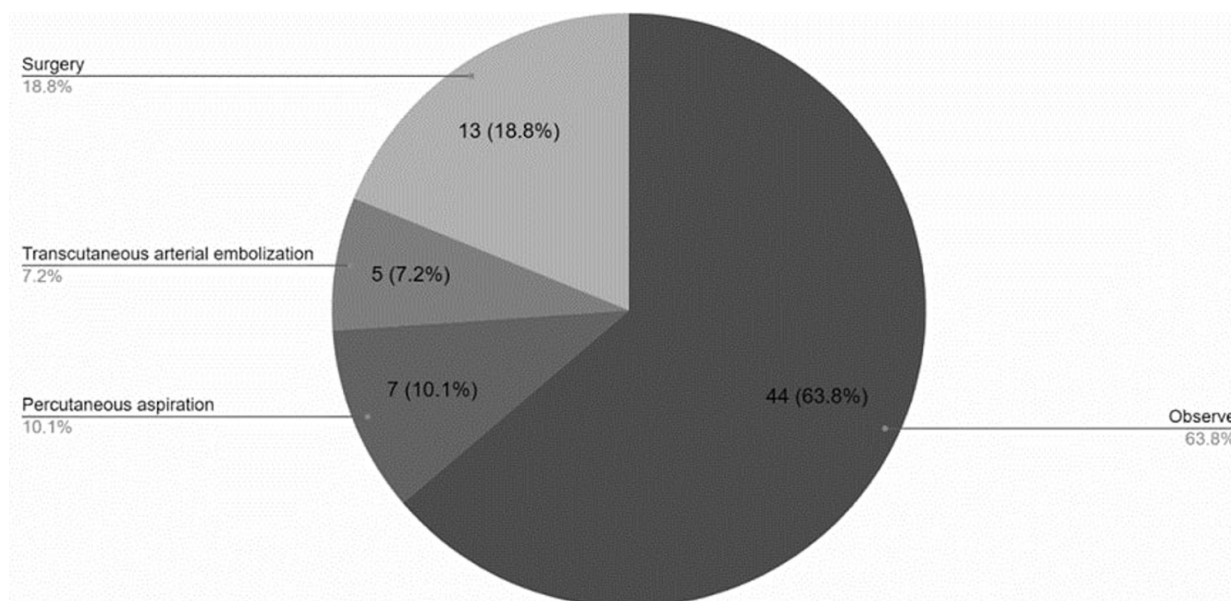


Figure 3 - Treatment modalities.

Table 3 - Managements and its outcomes.

Case No.	Author	Year of publication	Method of airway management	Treatment modalities	Acute complications	Cause of mortality	ICU
1	Smith et al ³⁹	1988	Tracheostomy	Observe	None	No	No
2	Myssiorek et al ¹⁰	1989	Endotracheal intubation	Percutaneous aspiration	None	No	No
3	Biby et al ⁴⁰	1990	Endotracheal intubation	Observe	None	No	No
4			First tried endotracheal intubation, then cricothyroidotomy	Observe	Anoxic brain damage	No	No
5			First tried endotracheal intubation, then cricothyroidotomy	Observe	None	No	No
6			Endotracheal intubation	Observe	None	No	No
7			Tracheostomy	Observe	Difficulty swallowing solid foods for months	No	No
8	Kuhn et al ²⁹	1991	First tried endotracheal intubation, then cricothyroidotomy	Observe	Respiratory arrest	No	No
9			Tracheostomy	Observe	Fatal pneumonia and multiple organ failure	No	No
10			Endotracheal intubation	Observe	Respiratory arrest	No	No
11			First tried endotracheal intubation, then tracheostomy	Observe	Cardiopulmonary arrest	No	No
12	Daniello et al ⁴¹	1994	First tried endotracheal intubation, then cricothyroidotomy	Observe	Non	No	No
13	Shaw et al ⁴²	1995	Tracheostomy	Observe	None	No	No
14	Mitchell et al ¹¹	1995	Endotracheal intubation	Percutaneous aspiration	None	No	No
15	O'Donnell et al ⁴³	1997	First tried endotracheal intubation, then tracheostomy	Observe	None	Multisystem organ failure	Yes
16	Mazzon et al ⁴⁴	1998	First tried endotracheal intubation, then tracheostomy	Observe	None	No	Yes
17	Cox et al ⁴⁵	1998	Endotracheal intubation	Observe	None	No	Yes
18	Senthuran et al ¹³	1999	First tried endotracheal intubation, then tracheostomy	Observe	Pneumonia, left arm swelling, subclavian and internal jugular vein thrombus	No	Yes
19	Sandooram et al ⁹	2000	First tried endotracheal intubation, then tracheostomy	Observe	None	No	No
20	Vakees et al ⁴⁶	2000	Endotracheal intubation	Percutaneous aspiration	None	No	No
21	Kette et al ⁴⁷	2000	Not mentioned	Observe	None	No	Yes
22	El Kettani et al ⁴⁸	2002	Not mentioned	Observe	None	No	Yes
23	Van Velde et al ⁴⁹	2002	Endotracheal intubation	Observe	None	No	No
24	Shiratori et al ⁵⁰	2003	Endotracheal intubation	Observe	None	No	No

Table 3 - Managements and its outcomes. Continuation

Case No.	Author	Year of publication	Method of airway management	Treatment modalities	Acute complications	Cause of mortality	ICU
25	Kochilas et al ⁵¹	2004	Endotracheal intubation	Transcutaneous arterial embolization	None	No	Yes
26	Suzuki et al ³³	2004	First tried endotracheal intubation, then tracheostomy	Observe	None	Hemodynamically unstable	Yes
27	Anagnostara et al ⁵²	2005	Endotracheal intubation	Observe	None	No	No
28	Chiti-Batelli et al ⁵³	2005	Endotracheal intubation	Observe	None	No	No
29	Duvillard et al ⁵⁴	2005	Tracheostomy	Observe	None	No	No
30		2005	Endotracheal intubation	Percutaneous aspiration	None	No	No
31	Freeman et al ⁵⁵	2005	Tracheostomy	Percutaneous aspiration	None	No	No
32	Lin et al ³²	2006	Not mentioned	Observe	None	No	Yes
33	Sheah et al ⁵⁶	2006	Endotracheal intubation	Observe	None	No	No
34	Wyngaert et al ⁵⁷	2006	First tried endotracheal intubation, then tracheostomy	Observe	None	No	No
35	Takeuchi et al ⁵⁸	2007	Endotracheal intubation	Transcutaneous arterial embolization	None	No	No
36	Lazott et al ⁵⁹	2007	Not mentioned	Observe	None	No	Yes
37	Srivastava et al ⁶⁰	2008	Endotracheal intubation	Surgery	Pulmonary oedema, type 2 respiratory failure	No	Yes
38	Tsai et al ³⁰	2008	Endotracheal intubation	Surgery	None	No	No
39	Birkholz et al ⁶¹	2010	Endotracheal intubation	Observe	None	No	No
40	Morita et al ⁶²	2010	Tracheostomy	Observe	None	No	No
41	Wronka et al ⁶³	2011	First tried endotracheal intubation, then tracheostomy	Surgery	None	No	No
42	Pfeiffer et al ⁶⁴	2011	Endotracheal intubation	Observe	None	No	No
43	Lin et al ⁶⁵	2011	First tried endotracheal intubation, then tracheostomy	Observe	None	No	No
44	Ottaviani et al ⁶⁶	2011	Endotracheal intubation	Percutaneous aspiration	None	No	No
45	Can Senel et al ³⁸	2012	Endotracheal intubation	Observe	None	Multiple organ failure	Yes
46	Jakanani et al ⁶⁷	2012	Endotracheal intubation	Percutaneous aspiration	None	No	No
47	Nurata et al ⁶⁸	2012	First tried endotracheal intubation, then tracheostomy	Observe	None	No	No
48	Iizuka et al ⁶⁹	2012	Endotracheal intubation	Transcutaneous arterial embolization	None	No	Yes
49	Paul et al ⁷⁰	2015	Not mentioned	Observe	None	Multiple organ failure	Yes
50	Thamamongood et al ⁷¹	2015	Endotracheal intubation	Observe	None	No	Yes
51	Park et al ⁷²	2015	Tracheostomy	Surgery	None	No	No
52		2015	Not mentioned	Observe	None	No	No

Table 3 - Managements and its outcomes. Continuation

Case No.	Author	Year of publication	Method of airway management	Treatment modalities	Acute complications	Cause of mortality	ICU
53	Calogero et al ⁷³	2015	Endotracheal intubation	Surgery	haemorrhage from the branches of the internal thoracic artery	No	No
55	Lowe et al ⁷⁵	2017	Endotracheal intubation	Transcutaneous arterial embolization	None	No	No
56	Betten et al ⁷⁶	2018	Endotracheal intubation	Transcutaneous arterial embolization	None	Multiple organ failure	No
57	Ren et al ⁷⁷	2019	Tracheostomy	Surgery	None	No	No
58	Devarakonda et al ⁷⁸	2019	First tried endotracheal intubation, then tracheostomy	Surgery	Submucosal swelling in the posterior wall of the pharynx, at the naso-oro junction, approximating the outline of the endotracheal tube	No	Yes
59	Chang et al ⁷⁹	2019	Endotracheal intubation	Surgery	None	No	No
60		2019	Not mentioned	Surgery	None	No	No
61	Arai et al ⁸⁰	2020	Not mentioned	Observe	None	No	No
62	Yu et al ⁸¹	2020	Endotracheal intubation	Observe	None	No	No
63	Iida et al ⁸²	2020	Endotracheal intubation	Observe	None	No	No
64	Baek et al ⁸³	2020	First tried endotracheal intubation, then tracheostomy	Surgery	None	No	No
65	Kitai et al ⁸⁴	2021	Endotracheal intubation	Observe	None	No	No
66		2021	Endotracheal intubation	Surgery	Diffuse mucosal oedema and copious secretions	No	No
66	Patel et al ⁸⁵	2021	Endotracheal intubation	Surgery	Diffuse mucosal oedema and copious secretions	No	No

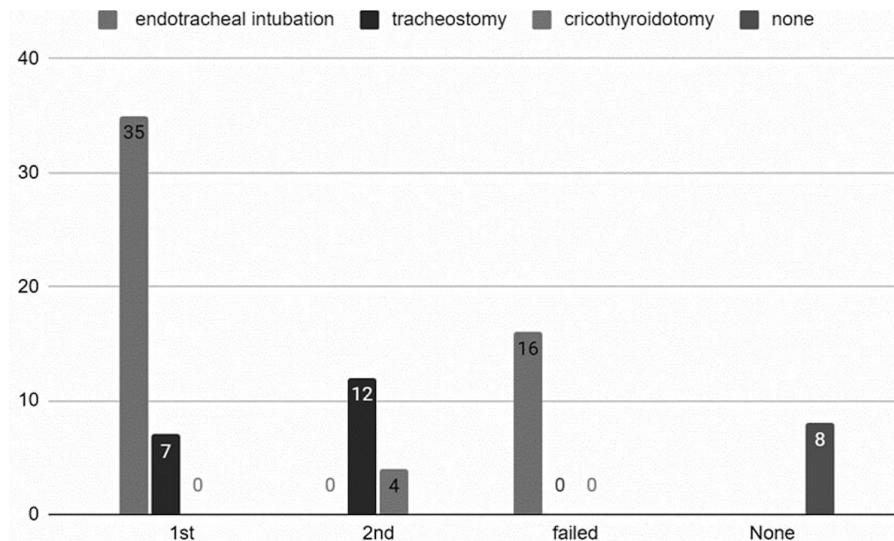


Figure 4 - Patient's airway management.

brachial plexus injuries, thoracic aortic dissection, cranial nerve VI palsy, and rib and skull fractures. Additionally, we found that most cases of traumatic RH occurred following a cervical vertebral fracture between C4 and C5. Especially in geriatric patients, falls constitute a significant contributor of morbidity and mortality, which is consistent with our findings (**Table 1**).

Tsao et al³⁵ found that falling accidents are the leading cause of RH, with symptoms typically appearing within the first 24 hours of blunt trauma. It is therefore critical to monitor patients closely and inform them and their caregivers that symptoms may persist for up to 24 hours after a serious injury.

According to our review, the median age of all cases reported was 68 years, with males constituting the majority. Those receiving anticoagulants or those with coagulation disorders are at an increased risk of bleeding.⁸⁸ An additional study carried out by Shiba et al⁸⁸ indicated similar results with a median age of 69 and a male dominance distribution. It was also found in the same study by Shiba et al,⁸⁸ that high bleeding was associated with international normalized ratio of 4.5 and above. Sagittal CT images demonstrated significantly wider hematomas in the intubated group. A significant number of large hematomas were observed even in patients who did not take antiplatelet or anticoagulant medications.

Symptoms. Due to the close proximity to the upper airway, the most common RH symptoms were respiratory symptoms (**Figure 2**), which usually developed within the first 24 hours, indicating that close monitoring and immediate treatment should be sought during this period.

Radiological findings. An imaging study of the neck (typically a CT scan or an MRI) is carried out by trauma surgeons and emergency physicians to evaluate whether RH is compromising the airway and the severity of the problem.

Most studies we included reported CT scan findings consistent with our findings, including: cases of RHs (n=26, 38%), prevertebral soft tissue swelling (n=10, 15%), prevertebral hematomas (n=10, 15%), cervical fractures (n=9, 13%), hypoattenuating retropharyngeal collection (n=1, 2%), occipital condylar fractures (n=2, 3%), retropharyngeal soft tissue swelling (n=4, 6%), pharyngeal mass (n=5, 7%), and cervical spondylosis (n=1, 0.2%, **Table 2**). Shiba et al⁸⁸ reported a median width of 2.2 cm for the hematoma on sagittal CT images. The presence of a wider hematoma on sagittal CT images indicates that earlier intubation is necessary.⁸⁸ According to other previous studies, the hematoma

diameter in intubated patients ranged from 1.5-3.6 cm.^{11,32,73} This was similar to the median diameter of the hematoma in the intubated cases in Shiba study.⁸⁸ These results confirm the predictive value of hematoma size in predicting the need for early intubation. Therefore, a large hematoma on sagittal CT images should be considered a red flag for early intubation.

An additional study carried out by Taso et al,³⁵ found that roentgenography (77.9%) of the neck or cervical spine was the primary diagnostic tool, and only 1 out of 53 images failed to reveal the presence of an enlarged prevertebral space. Other diagnostic methods included CT of the neck (67.6%), a fiberscope (42.6%), angiograms (14.7%), MRI of the neck (13.2%), and autopsy (2.9%).³⁵ Most studies, however, used CT scans as the first line of diagnostic testing.³⁵

In a study by Anagnostara et al,⁵² MRI findings were similar, with prevertebral edema, and minimal residual hyperdense or hypodense retropharyngeal tissue on T2 and hypointense retropharyngeal collection on T1. In addition to the neurologic examination, an MRI was carried out in order to diagnose spinal cord injury. The clinical assessments were not standardized and were carried out based on the standard of care of each center.³⁵

Treatment modalities. According to several previous studies that have described the time course between trauma and intubation, respiratory collapse usually occurs between 2 and 17 hours after trauma.^{12,84,89} As soon as RH is diagnosed, intubation should be carried out to prevent sudden airway obstruction. The use of early intubation may be beneficial for patients who are older and have low hemoglobin levels and platelet counts.^{35,88} The timing of intubation is also determined by physical findings, such as stridor and swelling of the neck.^{35,88}

In our study, the majority of cases were observed (n=44, 63.8%), followed by surgery (n=13, 18.8%), percutaneous aspiration (n=7, 10.1%), and transcatheter arterial embolization (n=5, 7.2%). Among the 62 cases, only 16 (23%) were admitted to the ICU (**Figure 3**).

It was reported by Shiba et al⁸⁸ that approximately half of the intubated patients required tracheotomies, with tracheotomies being carried out on the third day of illness on average. In previous studies, all patients evaluated underwent tracheotomies within 4 days of admission. Laryngoscopy or follow-up imaging was used in some studies to determine whether tracheotomies were necessary. In our current study, most patients underwent intubation (**Figure 4**).

A study by Karmacharyaya et al¹ concluded that 48.65% of cases were managed conservatively, with the remaining requiring cricothyrotomy or intubation, with a resolution time of 7.69 ± 5.44 days.

Over 40% of patients in the Shiba study⁸⁸ required transfer to another hospital for rehabilitation. Patients discharged to home and those discharged to other hospitals were compared in terms of their baseline characteristics. Baseline characteristics, such as age, intubation, duration of ICU stay, and duration of mechanical ventilation, did not differ significantly between the 2 groups.

Among patients with traumatic RH, acute airway obstruction is one of the leading causes of death. Thus, maintaining airway patency is crucial for the initial care of patients with RH. Endotracheal intubation is the initial step in airway management and observation and conservative management are the most common treatment options for traumatic RH. Despite being a classic method of locating the source of bleeding, halting the bleeding, and removing hematomas, surgery can be complicated when dealing with patients who have sustained injuries to their head and neck. Due to improvements in imaging and endovascular techniques, transarterial embolization and percutaneous aspiration are now commonly used along with nonoperative treatment.

Study limitations. First, intubation was determined by each physician, and intubation protocols are not standardized. This has resulted in a lack of clarity regarding the exact indications for intubation. Some patients were also prophylactically intubated. Additionally, our study involved a relatively small number of patients. No data were obtained regarding hematoma expansion time course. Thus, the rate of hematoma expansion could not be predicted or pinpointed, nor could the appropriate time of intubation.

Accordingly, future studies should address and establish a protocol for when intubation should be used in such cases. A comprehensive understanding of the course of Traumatic RH should be achievable by using a larger sample size and more detailed presentation.

In conclusion, traumatic RH is a life-threatening event where a swelling hematoma may fully obstruct the airway. Retropharyngeal hematoma primarily occurs due to cervical trauma, with falling being the most prevalent cause. Most traumatic RHs arise after cervical vertebral fractures. The majority of the injuries (50.0%) were cervical spinal injuries. The majority of patients were older, with a median age of 68 years for all occurrences that were documented. Dyspnea was the most prevalent symptom (66.6%), and the majority of

patients presented symptoms during the first 24 hours. Observation was the most prevalent treatment modality for 50% of the patients, and endotracheal intubation was the most common airway management method.

Acknowledgment. The authors gratefully acknowledge Editage (www.editage.com) for their English language editing.

References

1. Karmacharya P, Pathak R, Ghimire S, Shrestha P, Ghimire S, Poudel DR, et al. Upper airway hematoma secondary to warfarin therapy: a systematic review of reported cases. *N Am J Med Sci* 2015; 7: 494-502.
2. Mackenzie JW, Jellicoe JA. Acute upper airway obstruction. Spontaneous retropharyngeal haematoma in a patient with polycythaemia rubra vera. *Anaesthesia* 1986; 41: 57-60.
3. Feild JR, DeSaussure RL Jr. Retropharyngeal hemorrhage with respiratory obstruction following arteriography. Case report. *J Neurosurg* 1965; 22: 610-611.
4. Takanami I, Abiko T, Koizumi S. Life-threatening airway obstruction due to retropharyngeal and cervicomediastinal hematomas following stellate ganglion block. *Thorac Cardiovasc Surg* 2009; 57: 311-312.
5. Dedouit F, Grill S, Guilbeau-Frugier C, Savall F, Rougé D, Telmon N. Retropharyngeal hematoma secondary to cervical spine surgery: report of one fatal case. *J Forensic Sci* 2014; 59: 1427-1431.
6. Cho SY, Woo JH, Kim YJ, Chun EH, Han JI, Kim DY, et al. Airway management in patients with deep neck infections: a retrospective analysis. *Medicine (Baltimore)* 2016; 95: e4125.
7. Rountree KM, Zachwieja JA, Coleman JA, Hinton IJ, Lopez PP. That's no bee sting: penetrating neck trauma with isolated vertebral artery injury. *Am Surg* 2018; 84: e431-e433.
8. Muñoz A, Fischbein NJ, de Vergas J, Crespo J, Alvarez-Vincent J. Spontaneous retropharyngeal hematoma: diagnosis by mr imaging. *AJNR Am J Neuroradiol* 2001; 22: 1209-1211.
9. Sandooram D, Chandramohan AR, Radcliffe G. Retropharyngeal haematoma causing airway obstruction: a multidisciplinary challenge. *J Laryngol Otol* 2000; 114: 706-708.
10. Myssiorek D, Shalmi C. Traumatic retropharyngeal hematoma. *Arch Otolaryngol Head Neck Surg* 1989; 115: 1130-1132.
11. Mitchell RO, Heniford BT. Traumatic retropharyngeal hematoma--a cause of acute airway obstruction. *J Emerg Med* 1995; 13: 165-167.
12. McLaughlan CA, Pidsley R, Vandenberk PJ. Minor trauma--major problem. Neck injuries, retropharyngeal haematoma and emergency airway management. *Arch Emerg Med* 1991; 8: 135-139.
13. Senthuran S, Lim S, Gunning KE. Life-threatening airway obstruction caused by a retropharyngeal haematoma. *Anaesthesia* 1999; 54: 674-678.
14. Alexander DW, Leonard JR, Trail ML. Vascular complications of deep neck abscesses. A report of four cases. *Laryngoscope* 1968; 78: 361-370.
15. Levitt GW. The surgical treatment of deep neck infections. *Laryngoscope* 1971; 81: 403-411.

16. O'Neill JV, Toomey JM, Snyder GG 3rd. Retropharyngeal hematoma secondary to minor blunt trauma in the elderly patient. *J Otolaryngol* 1977; 6: 43-46.
17. Miller CH 3rd. Retropharyngeal hematomas. *Minn Med* 1970; 53: 887-888.
18. Epstein AM, Klassen KP. Spontaneous superior mediastinal hemorrhage. *J Thorac Cardiovasc Surg* 1960; 39: 740-745.
19. DiFrancesco RC, Escamilla JS, Sennes LU, Voegles RL, Tsuji DH. Spontaneous cervical hematoma: a report of 2 cases. *Ear Nose Throat J* 1999; 78: 168-175.
20. Al-Fallouji HK, Snow DG, Kuo MJ, Johnson PJ. Spontaneous retropharyngeal haematoma: 2 cases and a review of the literature. *J Laryngol Otol* 1993; 107: 649-650.
21. Ku P, Scott P, Kew J, van Hasselt A. Spontaneous retropharyngeal haematoma in a parathyroid adenoma. *Aust N Z J Surg* 1998; 68: 619-621.
22. Shanley CJ, Overbeck MC, Mazzara P, McLeod MK, Thompson NW, Rodriguez JL. Traumatic rupture of a cervical parathyroid adenoma. *Surgery* 1994; 115: 394-397.
23. Clark WG, Monks CJ. Retropharyngeal haematoma. *J Laryngol Otol* 1969; 83: 1039-1042.
24. Chin KW, Sercarz JA, Wang MB, Andrews R. Spontaneous cervical hemorrhage with near-complete airway obstruction. *Head Neck* 1998; 20: 350-353.
25. Bloom DC, Haegen T, Keefe MA. Anticoagulation and spontaneous retropharyngeal hematoma. *J Emerg Med* 2003; 24: 389-394.
26. O'Sullivan JL, Haedicke GJ, Bevivino J. Spontaneous postpartum factor VIII inhibitor development with bleeding into the face and neck. *Plast Reconstr Surg* 1989; 84: 802-805.
27. Sinert R, Scalea T. Retropharyngeal and bowel hematomas in an anticoagulated patient. *Acad Emerg Med* 1994; 1: 67-72.
28. Penning L. Prevertebral hematoma in cervical spine injury: incidence and etiologic significance. *AJR Am J Roentgenol* 1981; 136: 553-561.
29. Kuhn JE, Graziano GP. Airway compromise as a result of retropharyngeal hematoma following cervical spine injury. *J Spinal Disord* 1991; 4: 264-269.
30. Tsai SH, Hsu CW, Chu SJ. Traumatic retropharyngeal hematoma after a minor head injury. *J Trauma* 2008; 64: 539.
31. Tsai KJ, Huang YC. Traumatic retropharyngeal hematoma: case report. *J Trauma - Inj Infect Crit Care* 1999; 46: 715-716.
32. Lin JY, Wang CH, Huang TW. Traumatic retropharyngeal hematoma: case report. *Auris Nasus Larynx* 2007; 34: 423-425.
33. Suzuki T, Imai H, Uchino M, Wakita R, Endo M, Kitahara T, et al. Fatal retropharyngeal haematoma secondary to blunt trauma. *Injury* 2004; 35: 1059-1063.
34. Tenofsky PL, Porter SW, Shaw JW. Fatal airway compromise due to retropharyngeal hematoma after airbag deployment. *Am Surg* 2000; 66: 692-694.
35. Tsao YL, Hsu CC, Chen KT. Blunt traumatic retropharyngeal hematoma with respiratory symptoms: a systematic review of reported cases. *Emerg Med Int* 2021; 2021: 5158403.
36. Kashiwagi M, Ikeda N, Tsuji A, Kudo K. Sudden unexpected death following stellate ganglion block. *Leg Med (Tokyo)* 1999; 1: 262-265.
37. Capps RB. Multiple parathyroid tumors with massive mediastinal and subcutaneous hemorrhage. *Am J Med Sci* 1934; 188: 800-804.
38. Senel AC, Gunduz AK. Retropharyngeal hematoma secondary to minor blunt neck trauma: case report. *Rev Bras Anesthesiol* 2012; 62: 731-735.
39. Smith JB, Morrissey P, Hemmick RS, Haas AF, Bodai BI. Retropharyngeal hematomas. *J Trauma* 1988; 28: 553-554.
40. Biby L, Santora AH. Prevertebral hematoma secondary to whiplash injury necessitating emergency intubation. *Anesth Analg* 1990; 70: 112-114.
41. Daniello NJ, Goldstein SI. Retropharyngeal hematoma secondary to minor blunt head and neck trauma. *Ear Nose Throat J* 1994; 73: 41-43.
42. Shaw CB, Bawa R, Snider G, Wax MK. Traumatic retropharyngeal hematoma: a case report. *Otolaryngol Head Neck Surg* 1995; 113: 485-488.
43. O'Donnell JJ, Birkinshaw R, Harte B. Mechanical airway obstruction secondary to retropharyngeal haematoma. *Eur J Emerg Med* 1997; 4: 166-168.
44. Mazzone D, Zanatta P, Curtolo S, Bernardi V, Bosco E. Upper airway obstruction by retropharyngeal hematoma after cervical spine trauma: report of a case treated with percutaneous dilational tracheostomy. *J Neurosurg Anesthesiol* 1998; 10: 237-240.
45. Cox RG. Retropharyngeal haematoma leading to airway obstruction in a child with closed head trauma. *Paediatr Anaesth* 1998; 8: 353-356.
46. Vakees YS, Hashemi K, Freij R. Retropharyngeal haematoma after blunt trauma. *J Accid Emerg Med* 2000; 17: 430.
47. Kette F, Mergoni P, Girardis M, Sabbadini D, Zauli M, Sussi L, et al. Delayed upper airway obstruction following a retropharyngeal haematoma after minor head trauma. *Eur J Emerg Med* 2000; 7: 301-303.
48. El Kettani C, Badaoui R, Lesoin FX, Le Gars D, Ossart M. Traumatic retropharyngeal hematoma necessitating emergency intubation. *Anesthesiology* 2002; 97: 1645-1646.
49. Van Velde R, Sars PR, Olsman JG, Van De Hoeven H. Traumatic retropharyngeal haematoma treated by embolization of the thyrocervical trunk. *Eur J Emerg Med* 2002; 9: 159-161.
50. Shiratori T, Hara K, Ando N. Acute airway obstruction secondary to retropharyngeal hematoma. *J Anesth* 2003; 17: 46-48.
51. Kochilas X, Ali A, Montague ML, Kelleher RJ. Retropharyngeal space swelling secondary to minor blunt head and neck trauma. *J Laryngol Otol* 2004; 118: 465-467.
52. Anagnostara A, Athanassopoulou A, Kailidou E, Markatos A, Eystathidis A, Papageorgiou S. Traumatic retropharyngeal hematoma and prevertebral edema induced by whiplash injury. *Emerg Radiol* 2005; 11: 145-149.
53. Chiti-Batelli S, Vaz F, Coman S. Traumatic retropharyngeal haematoma in an anticoagulated patient: case report and proposal for a clinical protocol. *Acta Otolaryngol* 2005; 125: 443-445.
54. Duvillard C, Ballester M, Romanet P. Traumatic retropharyngeal hematoma: a rare and critical pathology needed for early diagnosis. *Eur Arch Otorhinolaryngol* 2005; 262: 713-715.
55. Freeman BJ, Behensky H. Bilateral occipital condyle fractures leading to retropharyngeal haematoma and acute respiratory distress. *Injury* 2005; 36: 207-212.
56. Sheah K, Hui F, Wansaicheong G, Khoo M. Retropharyngeal haemorrhage from a vertebral artery branch treated with distal flow arrest and particle embolisation. *Singapore Med J* 2006; 47: 719-723.
57. De Wyngaert R, Mulken T, Baeyaert M, Bellinck P, Salgado R, Ghijssen D, et al. Bilateral occipital condylar fracture with associated hematomas. *Emerg Radiol* 2006; 13: 79-82.

58. Takeuchi S, Kato H, Matsuzaki H, Takasato Y, Masaoka H, Hayakawa T, et al. [Prevertebral hematoma and traumatic atlantooccipital dislocation with survival--case report]. *Brain Nerve* 2007; 59: 1211-1214. [In Japanese].
59. Lazott LW, Ponzio JA, Puana RB, Artz KS, Ciceri DP, Culp WC Jr. Severe upper airway obstruction due to delayed retropharyngeal hematoma formation following blunt cervical trauma. *BMC Anesthesiol* 2007; 7: 2.
60. Srivastava S, Solanki T. Retropharyngeal haematoma - an unusual bleeding site in an anticoagulated patient: a case report. *Cases J* 2008; 1: 294.
61. Birkholz T, Kröber S, Knorr C, Schiele A, Bumm K, Schmidt J. A retropharyngeal-mediastinal hematoma with supraglottic and tracheal obstruction: the role of multidisciplinary airway management. *J Emerg Trauma Shock* 2010; 3: 409-411.
62. Morita S, Iizuka S, Hirakawa H, Higami S, Yamagiwa T, Inokuchi S. A 92-year-old man with retropharyngeal hematoma caused by an injury of the anterior longitudinal ligament. *Chin J Traumatol* 2010; 13: 120-122.
63. Wronka KS, Sznerch N, Davies J. Dysphagia and airway compromise as a result of retropharyngeal haematoma following undiagnosed odontoid peg fracture: a case report. *Ann R Coll Surg Engl* 2011; 93: e114-e116.
64. Pfeiffer J, Ridder GJ. An elderly woman with increasing dyspnoea after a fall. *Emerg Med J* 2011; 28: 806-808.
65. Lin M, Sinclair C. Retropharyngeal haematoma - an unusual cause of airway obstruction. *J Surg Case Rep* 2011; 2011: 5.
66. Ottaviani F, Schindler A, Mozzanica F, Peri A, Rezzonico S, Turiel M. Surgical management of a life-threatening retro-pharyngeal haematoma following trans-oesophageal echocardiography. *Acta Otorinolaryngol Ital* 2011; 31: 39-42.
67. Jakanani G, Kenningham R, Bolia A. Active retropharyngeal hemorrhage from an acute thyrocervical artery injury: a rare complication of hyperextension cervical spine injury. *J Emerg Med* 2012; 43: e39-e41.
68. Nurata H, Yilmaz MB, Borcek AO, Oner AY, Baykaner MK. Retropharyngeal hematoma secondary to whiplash injury in childhood: a case report. *Turk Neurosurg* 2012; 22: 521-523.
69. Iizuka S, Morita S, Otsuka H, Yamagiwa T, Yamamoto R, Aoki H, et al. Sudden asphyxia caused by retropharyngeal hematoma after blunt thyrocervical artery injury. *J Emerg Med* 2012; 43: 451-456.
70. Paul D, Sen S, Palai A, Mukherjee M. Retropharyngeal hematoma secondary to minor blunt trauma neck: a rare case report. *Bengal J Otolaryngol Head Neck Surg* 2015; 23: 34-38.
71. Thamamongood TA, Onuki T, Kuramochi M, Inagaki M. Posterior mediastinal hematoma after a simple fall in a patient with normal coagulation. *Acute Med Surg* 2015; 3: 43-45.
72. Park JH, Jeong EK, Kang DH, Jeon SR. Surgical treatment of a life-threatening large retropharyngeal hematoma after minor trauma : 2 case reports and a literature review. *J Korean Neurosurg Soc* 2015; 58: 304-307.
73. Calogero CG, Miller AC, Greenberg MR. Life-threatening retropharyngeal hemorrhage secondary to rupture of the inferior thyroid artery. *Case Rep Emerg Med* 2015; 2015: 789076.
74. Kudo S, Fukushima K, Hashimoto M, Furutake M, Tanaka K, Okada K. Airway and circulatory collapse due to retropharyngeal hematoma after blunt vertebral artery injury. *Am J Emerg Med* 2017; 35: 806.e5-806.e7.
75. Lowe E, Patil S. Management of subacute airway emergency after blunt neck trauma. *BMJ* 2017; 356: j141.
76. Betten DP, Jaquint JL. Traumatic retropharyngeal hematoma in a patient taking clopidogrel. *Case Rep Emerg Med* 2018; 2018: 6147473.
77. Ren H, Wang J, Yu L. Retropharyngeal hematoma following anterior cervical spine surgery: lessons from a case report (CARE-compliant). *Medicine (Baltimore)* 2019; 98: e17247.
78. Devarakonda BV, Issar Y, Goyal R, Vadapalli K. 'Where did the tube go?' A case of retropharyngeal submucosal false passage during nasal intubation. *Med J Armed Forces India* 2019; 75: 476-478.
79. Chang DG, Park JB, Cho YJ, Kim GU. Traumatic posterior atlantooccipital dislocation combined with type II dens fracture and C1 anterior arch fracture: 2 case reports. *Medicine (Baltimore)* 2019; 98: e17666.
80. Arai T, Asamoto S, Fukui Y, Endo T, Oshida K, Arai Y, et al. [A case of a massive retropharyngeal hematoma associated with traumatic cervical cord injury]. *No Shinkei Geka* 2020; 48: 707-710. [In Japanese].
81. Yu S, Lee JI, Lee JH, Kim BC, Ha MJ, Choi HJ. Traumatic retropharyngeal hematoma following cervical vascular injury: a case report. *Korean J Neurotrauma* 2020; 16: 343-347.
82. Iida A, Nishida A, Yoshitomi S, Nojima T, Naito H, Nakao A. Retropharyngeal hematoma presenting airway obstruction: a case report. *Int J Surg Case Rep* 2020; 77: 321-324.
83. Baek JH, Kim JH. Retropharyngeal hematoma secondary to cervical hyperextension in a minor collision trauma presenting with dyspnoea: a case report. *Medicine (Baltimore)* 2020; 99: e21528.
84. Kitai Y, Sato R. Delayed retropharyngeal hematoma following a minor facial blunt trauma. *Trauma Case Rep* 2021; 32: 100442.
85. Patel SV, Reza A, Rice SR. Mind the gap: life-threatening retropharyngeal haematoma resulting in acute airway obstruction following blunt trauma by closing train carriage doors. *BJR Case Rep* 2021; 7: 20200190.
86. Schulman S, Beyth RJ, Kearon C, Levine MN. Hemorrhagic complications of anticoagulant and thrombolytic treatment: American College of Chest Physicians Evidence-Based Clinical Practice Guidelines (8th edition). *Chest* 2008; 133: 257S-298S.
87. Evans D, Pester J, Vera L, Jeanmonod D, Jeanmonod R. Elderly fall patients triaged to the trauma bay: age, injury patterns, and mortality risk. *Am J Emerg Med* 2015; 33: 1635-1638.
88. Shiba D, Hifumi T, Tomiyama K, Tanaka M, Tanaka A, Ogawa K, et al. Traumatic retropharyngeal hematoma without spinal cord injury or spinal fracture: a retrospective multicenter analysis. *Eur J Trauma Emerg Surg* 2023; 49: 1477-1484.
89. Vierendeels C, Peeters X, Bosschaert P. Retropharyngeal hematoma under rivaroxaban: a rare entity to know for its risk of airway obstruction. *J Belg Soc Radiol* 2021; 105: 15.